

## NO. 085 Warthin tumor ( Papillary cystadenoma lymphomatosum )

<ul style="list-style-type: none"> <li>➤ 為 benign 的 tumor · 呈 well encapsulated · 將 tumor island 與 normal gland 分開。</li> <li>➤ Tumor island : 可看到很多的 cavity · 所以是 cystadenoma · 在 cyst 的地方 ; 可見 epithelium 伸入 cavity 內 · 呈 papillary projection · 故稱 papillary 。</li> <li>➤ Cavity 上有兩層的細胞構成的 lining epithelium · Lining epithelium 的細胞質是粉紅色 · 均勻且顆粒狀 · 內外兩層細胞型態不同 :             <ul style="list-style-type: none"> <li>■ 細胞靠近 cavity 那一層為 high columnar cell</li> <li>■ 細胞靠近 stroma 那一層為 low cuboidal cell</li> </ul> </li> <li>➤ Wall 上有很 dense 的 lymphocytes · 有時候多到可以形成 germinal center 。</li> </ul>	<p>標記重點 :</p> <ol style="list-style-type: none"> <li>1. Capsule (Fig. 1 red ↑)</li> <li>2. Normal salivary gland (Fig. 1 blue ↑)</li> <li>3. Papillary projection (Fig. 2 yellow ↑)</li> <li>4. Cystic structure             <ul style="list-style-type: none"> <li>● Lumen (Fig. 3 yellow ↑)</li> <li>● Lining epithelium (Fig. 3 red ↑)</li> <li>● Stroma (Fig. 3 blue ↑)</li> </ul> </li> <li>5. Lymphoid tissue ( with germinal center ) (Fig. 3 green ↑)</li> <li>6. Eosinophilic secretions (Fig. 3 black ↑)</li> <li>7. Double-cell layer lining epithelium :             <ul style="list-style-type: none"> <li>■ basal cells (Fig. 4 green ↑) : low cuboidal cell</li> <li>■ luminal cells (Fig. 4 blue ↑) : high columnar with abundant finely granular acidophilic cytoplasm ( like oncocyte )</li> </ul> </li> </ol>
--	--

Fig. 1

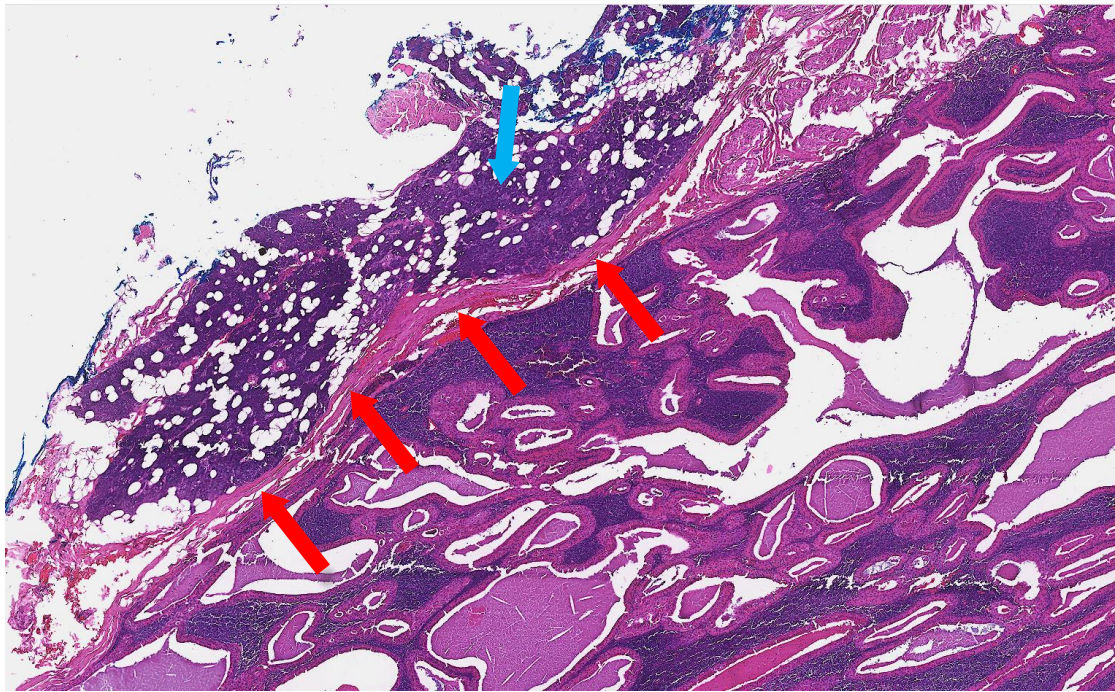


Fig. 2

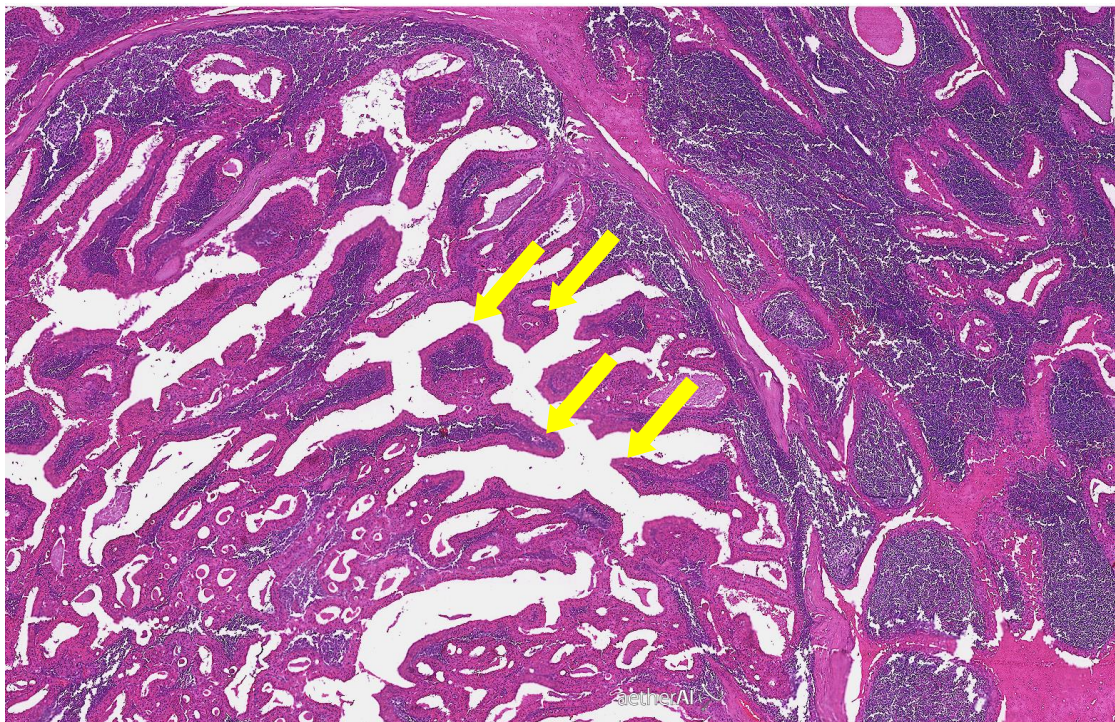


Fig. 3

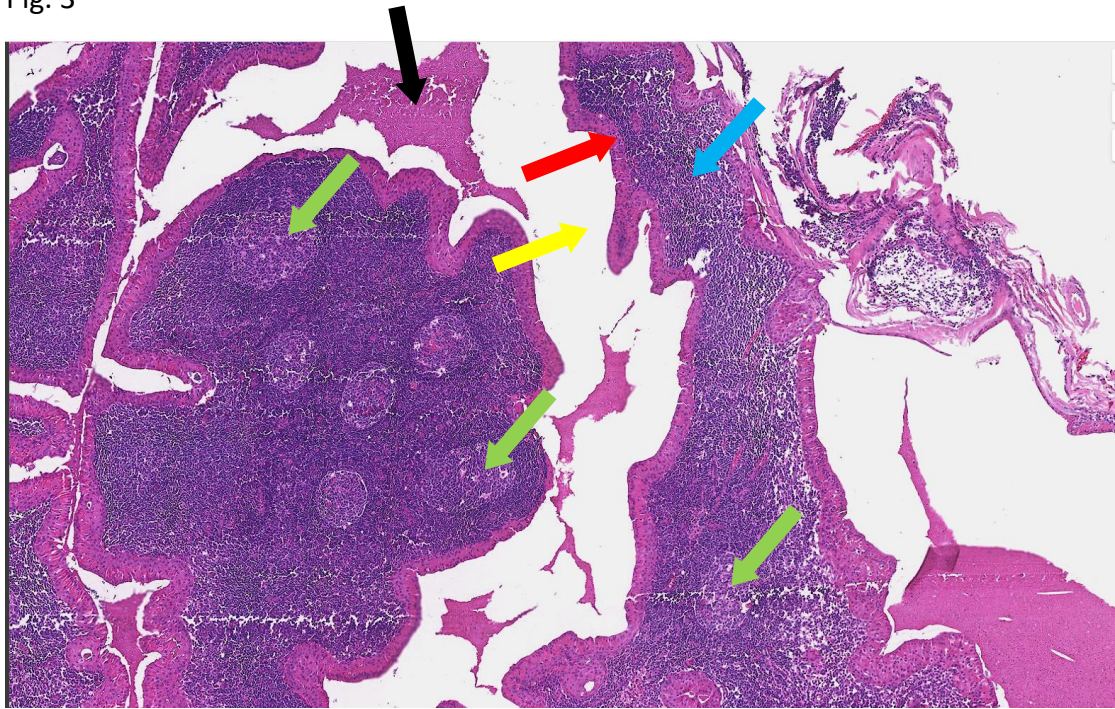


Fig. 4

