

## NO. 077 Fordyce Granules

<ul style="list-style-type: none"><li>➤ 在低倍下易見 sebaceous gland (Fig. 1 red ↑) 出現在表皮 ( parakeratinized ) (Fig. 1 blue ↑) 附近，是一團很明顯的透明空泡狀組織。</li><li>➤ Sebaceous gland 內部，可見 Sebaceous cells (Fig. 2 green ↑) 呈現空泡狀，中有淡染小顆粒。</li><li>➤ 可見 minor salivary gland (Fig. 3 yellow ↑)，加上有口腔上皮因此可知檢體來源自口腔。</li></ul>	<p>標記重點：</p> <ol style="list-style-type: none"><li>1. 似正常 skin 的 sebaceous glands ( 口腔內不應該有 ) (Fig. 1 red ↑)</li><li>2. Sebaceous cells (Fig. 2 green ↑) -- centrally located nuclei -- abundant foamy cytoplasm</li><li>3. Minor salivary gland (Fig. 3 yellow ↑)</li><li>4. Parakeratinized oral epithelium Fig. 1 blue ↑)</li></ol>
--	--

Fig. 1

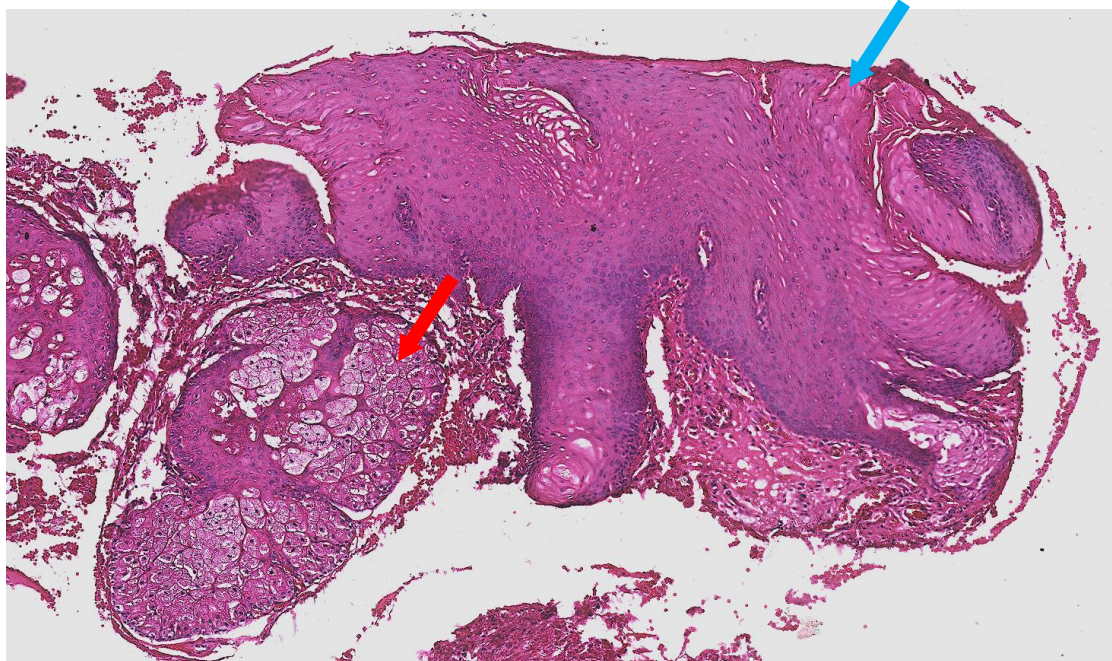


Fig. 2

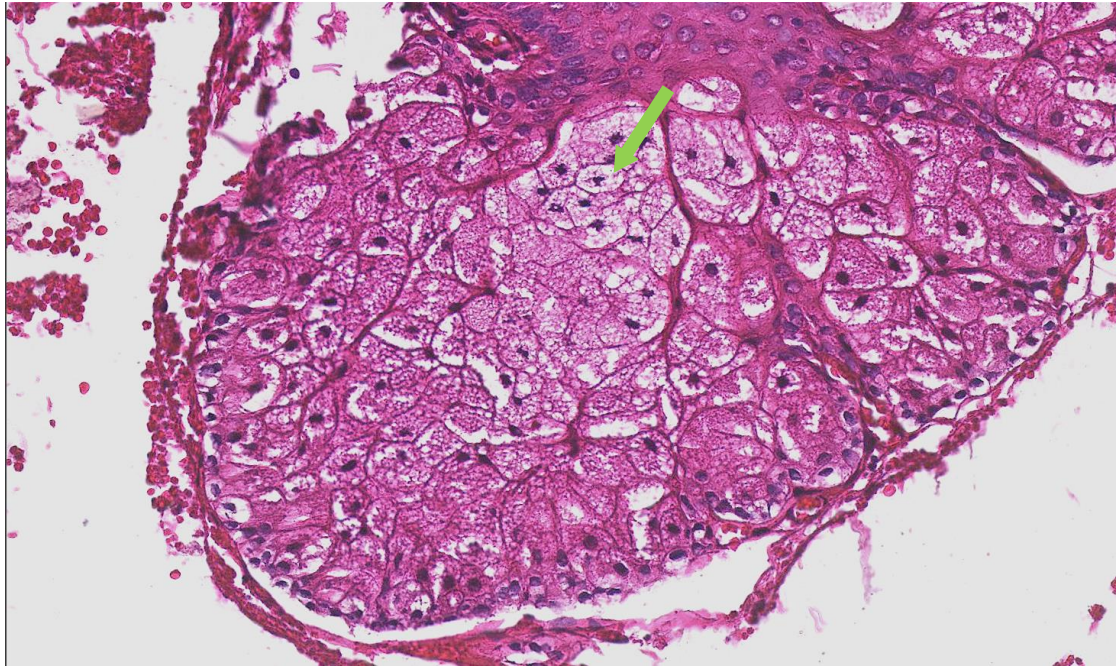


Fig. 3

