

NO. 075 Osteosarcoma, fibroblastic type

<ul style="list-style-type: none"> ➤ 有許多 atypical osteoblasts 形成 malignant bone 或類骨質(osteoid) ➤ 這些 atypical osteoblasts 呈現 pleomorphism、high N/C ratio、hyperchromatism ➤ Osteoid 呈現 thin, lace-like eosinophilic strands ➤ Osteosarcoma 依照顯微鏡下的型態可分做： <ul style="list-style-type: none"> ■ Chondroblastic ■ Osteoblastic ■ Fibroblastic：腫瘤細胞主要由 spindle cells (Fig. 1&3 green ↑) 所構成，其中夾雜一些 osteoid ■ Telangiectatic ■ Parosteal ■ Small cell 	<p>標記重點：</p> <ol style="list-style-type: none"> 1. Osteoid substance (Fig. 1&2 blue ↑) 2. Malignant osteoblasts (Fig. 2 yellow ↑) 3. Spindle cells (Fig. 1&3 green ↑) - abnormal mitosis (Fig. 2 red ↑) 4. Residual normal bone (Fig. 3 yellow ↑)
--	---

Fig. 1

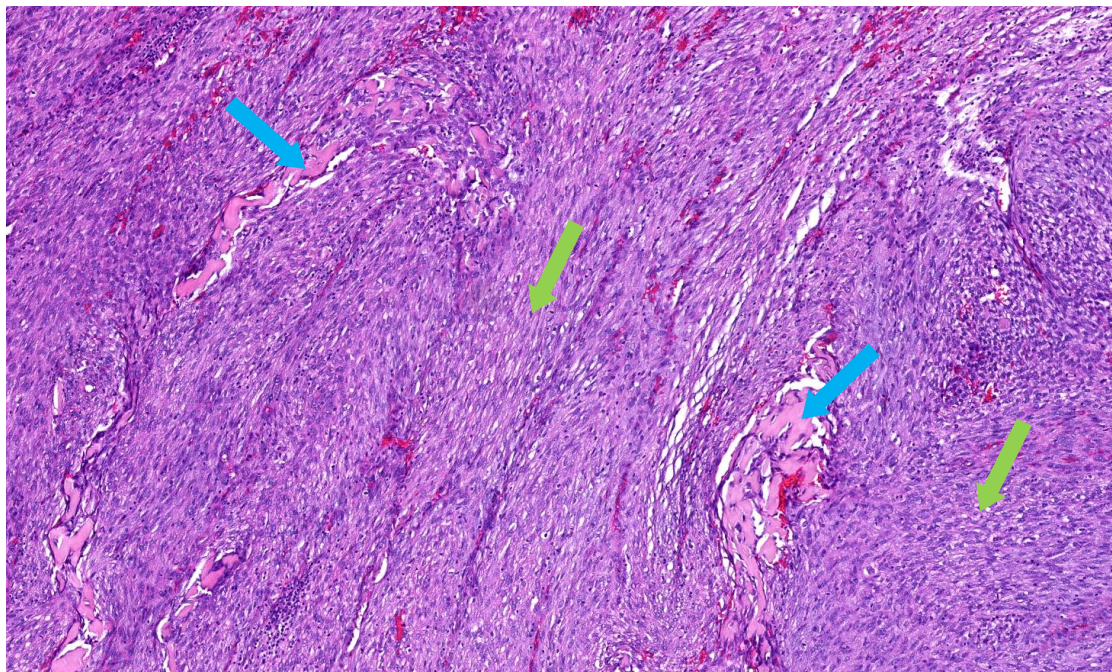


Fig. 2

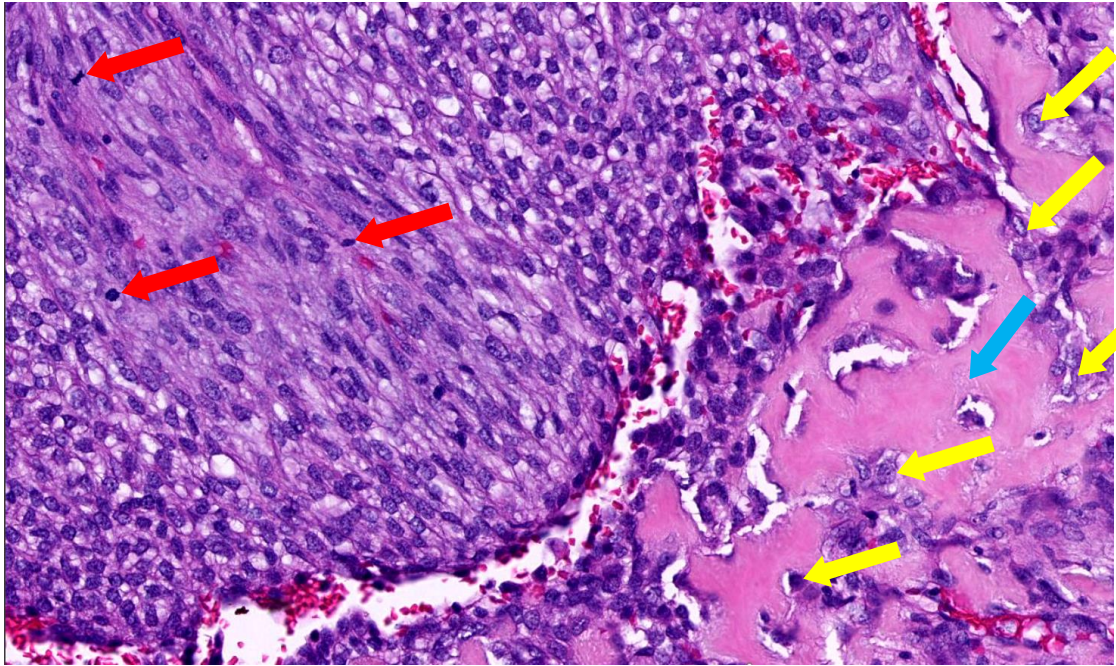


Fig. 3

