

NO. 074 Osteosarcoma, chondroblastic type

<ul style="list-style-type: none"> ➤ 有許多 atypical osteoblasts 形成 malignant bone 或類骨質(osteoid) ➤ 這些 atypical osteoblasts 呈現 pleomorphism、high N/C ratio、hyperchromatism ➤ Osteoid 呈現 thin, lace-like eosinophilic strands ➤ Osteosarcoma 依照顯微鏡下的型態可分做： <ul style="list-style-type: none"> - Chondroblastic：頭頸部最常見，也是此片的 type。其中可見軟骨的生成（顏色較藍）。 - Osteosarcoma 生成的 bone 與 cartilage 都是不正常的，裡頭的 osteocytes、chondrocytes 密度都很高，細胞也呈現 pleomorphism 與 high N/C ratio - Osteoblastic - Fibroblastic - Telangiectatic - Parosteal - Small cell 	<p>標記重點：</p> <ol style="list-style-type: none"> 1. Osteoid substance (Fig. 1 blue ↑) 2. Malignant osteoblasts (Fig. 1 yellow ↑) 3. Malignant bone (Fig. 3 red ↑) 4. Malignant cartilage (Fig. 2 green ↑) 5. Osteoclast (Fig. 3 blue ↑)
---	---

Fig. 1

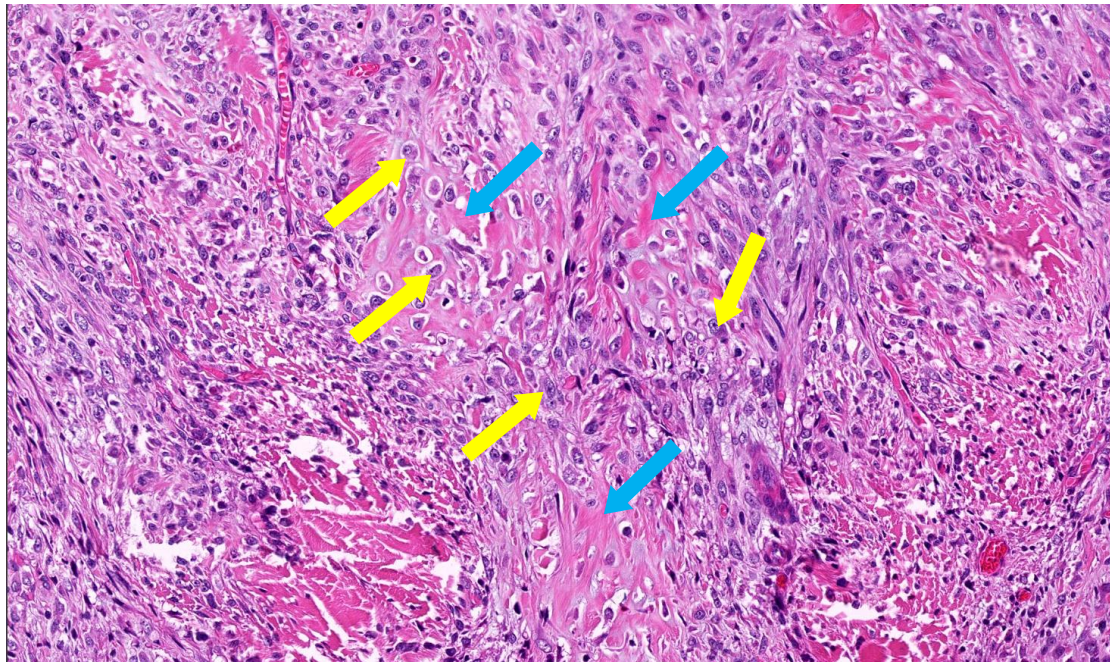


Fig. 2

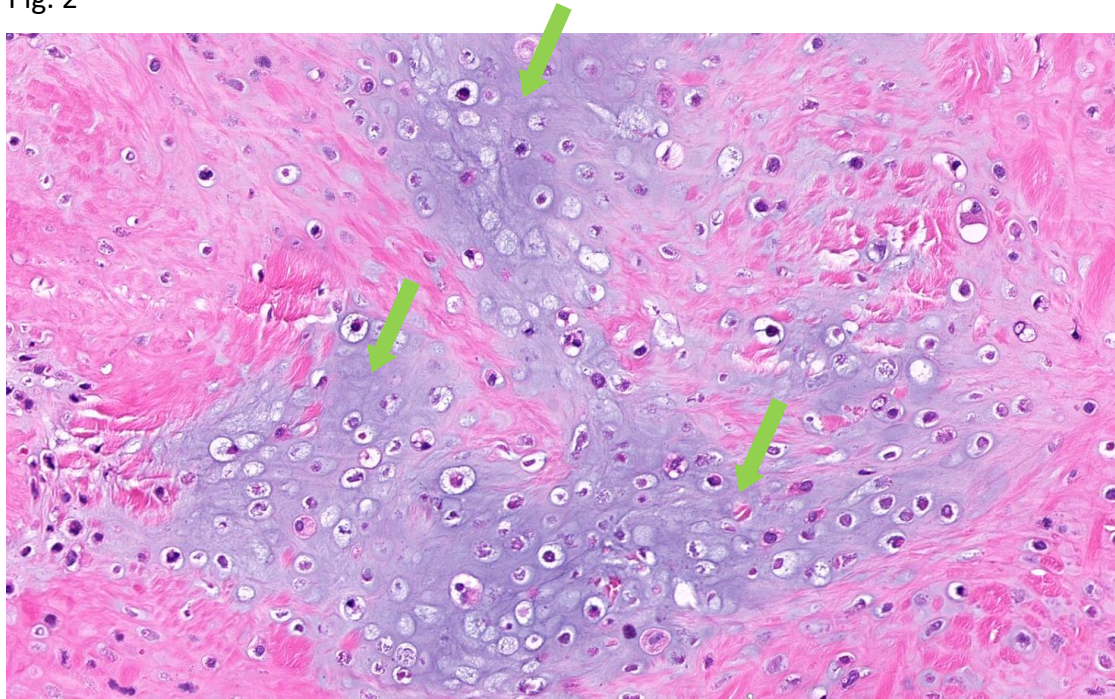


Fig. 3

