

## NO. 073 Giant cell granuloma, central

<ul style="list-style-type: none"><li>➤ 可見許多 multinucleated giant cells</li><li>➤ 背景為 granulation tissue of ovoid to spindle shaped fibroblasts (眾多的背景細胞)</li><li>➤ 有許多血管增生，也可見許多 RBC</li><li>➤ 由於是 central type，因此可見到骨頭。此 case 因為未經過脫鈣程序，骨頭呈現深紫色 (Fig. 1 blue ↑)，骨細胞細節較不清楚。</li></ul>	<p>標記重點：</p> <ol style="list-style-type: none"><li>1. 可由周圍是 bone 知為 central type (Fig. 1 blue ↑)</li><li>2. Multinucleated giant cells (Fig. 2 yellow ↑)</li><li>3. Blood vessel proliferation (Fig. 2 black ↑)</li><li>4. Granulation tissue of ovoid to spindle shaped fibroblasts (Fig. 2 red ↑)</li><li>5. Hemosiderin (Fig. 2 blue ↑)</li></ol>
--	--

Fig. 1

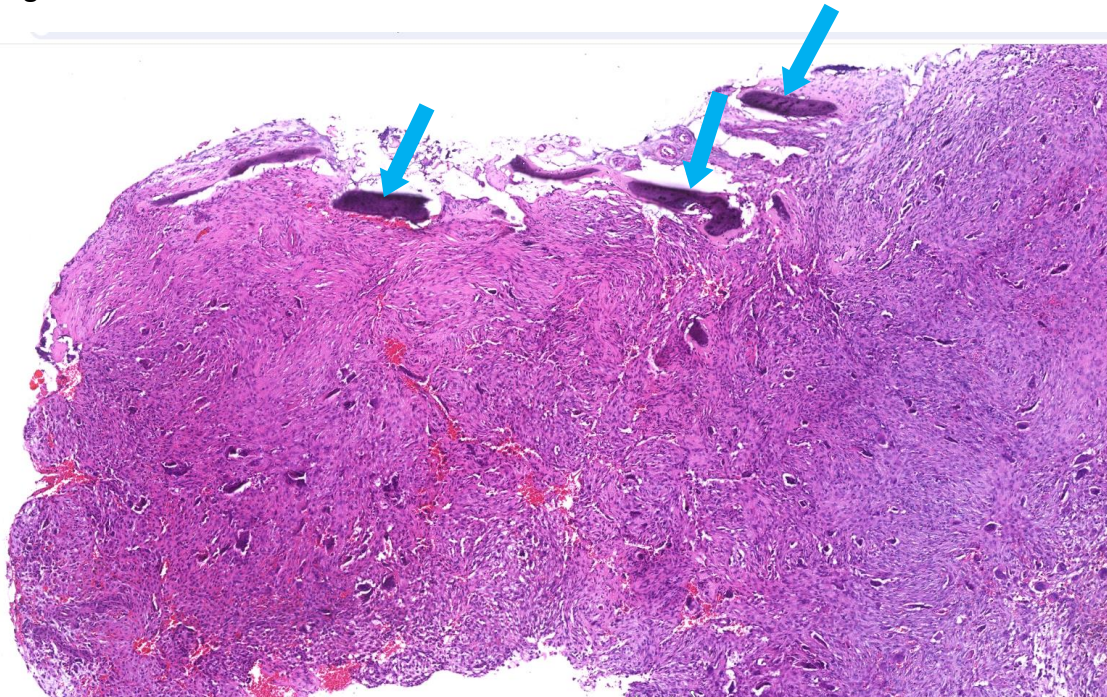


Fig. 2

