

## NO. 002 Moderate epithelial dysplasia with hyperparakeratosis

<ul style="list-style-type: none"> <li>➤ 此片病變在表皮層 · basement membrane 保持完整 · connective tissue 正常</li> <li>➤ 低倍下可發現 dysplastic epithelium 有以下特徵：             <ul style="list-style-type: none"> <li>a. Bulbous rete ridges (Fig 1. blue ↑)</li> <li>b. Loss of polarity</li> <li>c. Keratin or epithelial pearls (在非表層出現)</li> <li>d. Loss of typical epithelial cell cohesiveness (細胞彼此抓不緊) (Fig 2. green ↑)</li> </ul> </li> <li>➤ 高倍下上皮細胞出現 dysplastic change 有以下特徵：             <ul style="list-style-type: none"> <li>a. Enlarged nuclei and cells</li> <li>b. Increased nuclear-to-cytoplasmic ratio</li> <li>c. Hyperchromatic nuclei (細胞核濃染)</li> <li>d. Pleomorphic nuclei and cells (多形性)</li> <li>e. Dyskeratosis (不正常的角化)</li> <li>f. Increased mitotic activity (有絲分裂增加)</li> <li>g. Abnormal mitotic figure (不正常的有絲分裂)</li> <li>h. Large and prominent nucleoli (核仁明顯)</li> </ul> </li> <li>➤ 依照 dysplastic epithelial cells 占據的上皮層比例可分成以下三種：             <ul style="list-style-type: none"> <li>a. Dysplastic cells 占下 1/3 層：mild epithelial dysplasia</li> <li>b. Dysplastic cells 占 1/2 層：moderate epithelial dysplasia (Fig 1. green ↑)</li> <li>c. Dysplastic cells 占 2/3 層：severe epithelial dysplasia</li> </ul> </li> <li>➤ Carcinoma in situ 定義為由上到下 ( top to bottom ) 的上皮細胞都出現 dysplastic change 。</li> </ul>	<p>標記重點：</p> <ol style="list-style-type: none"> <li>1. Basement membrane 完整 ( SCC 的 basement membrane 不完整 · 有向下 invasion 的現象 )(Fig 1. red line)</li> <li>2. 上皮最表層之角質層增厚 · 其中可見細胞核 · 為 hyperparakeratosis (Fig 1. red ↑)</li> <li>3. 5 個特徵必標：             <ul style="list-style-type: none"> <li>a. Pleomorphism (Fig 3. blue ↑ 附近區域可見細胞型態變異大)</li> <li>b. Hyperchromatism (Fig 3. yellow ↑)</li> <li>c. Individual cell keratinization (Fig 3. red ↑)</li> <li>d. Abnormal mitosis (Fig 2 and 4. red ↑)</li> <li>e. N/C ratio 增加 (Fig 2. blue ↑)</li> </ul> </li> <li>4. 本 case 之 dysplastic cells 約佔 1/2~2/3 層之細胞 · 因此 moderate 或是 severe epithelial dysplasia 都是可以接受的診斷。</li> </ol>
---------------------------------------------------------------------------------------------------------------------------------------------------------------------------------------------------------------------------------------------------------------------------------------------------------------------------------------------------------------------------------------------------------------------------------------------------------------------------------------------------------------------------------------------------------------------------------------------------------------------------------------------------------------------------------------------------------------------------------------------------------------------------------------------------------------------------------------------------------------------------------------------------------------------------------------------------------------------------------------------------------------------------------------------------------------------------------------------------------------------------------------------------------------------------------------------------------------------------------------------------------------------------------------------------------------------------------------	---------------------------------------------------------------------------------------------------------------------------------------------------------------------------------------------------------------------------------------------------------------------------------------------------------------------------------------------------------------------------------------------------------------------------------------------------------------------------------------------------------------------------------------------------------------------------------------------------------------------------------------------------------------------------------------

Fig 1.

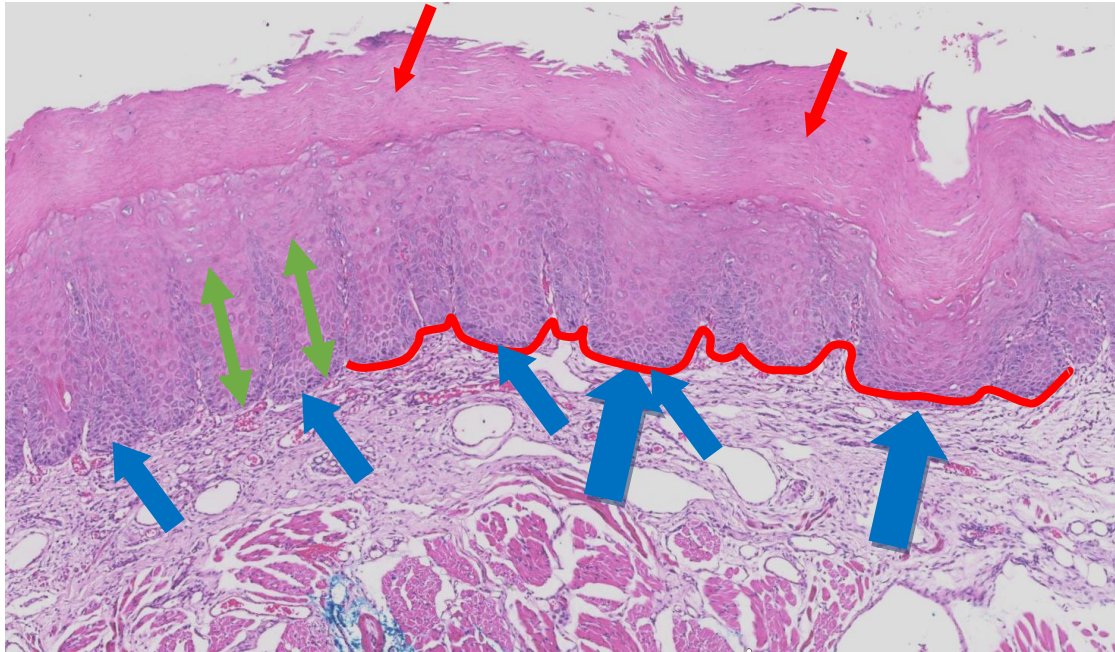


Fig 2.

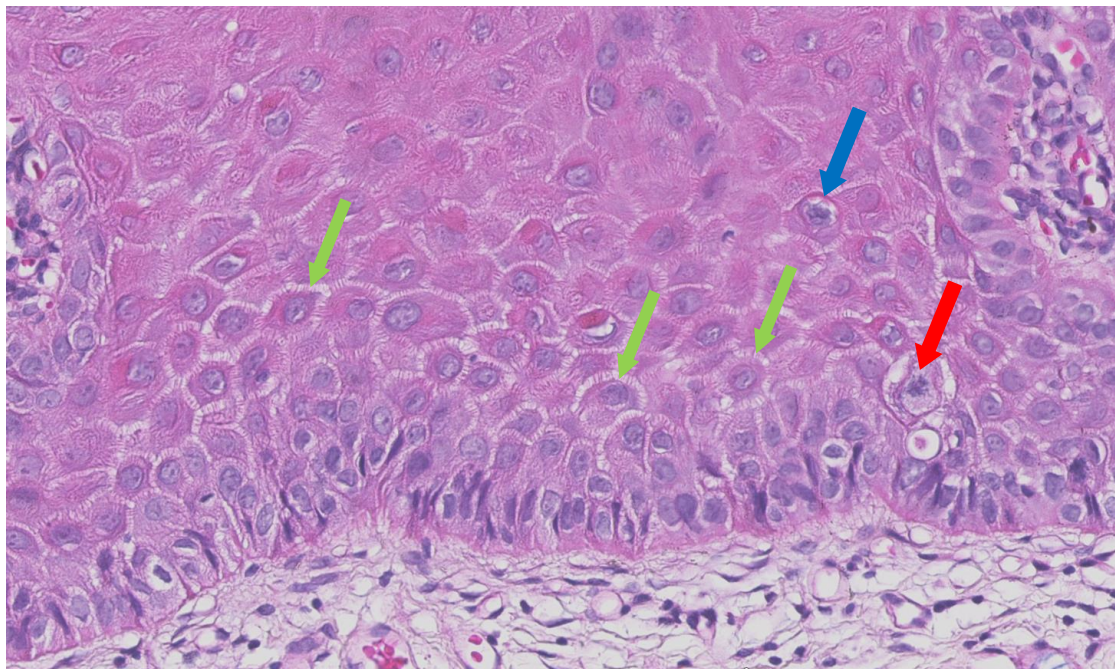


Fig 3.

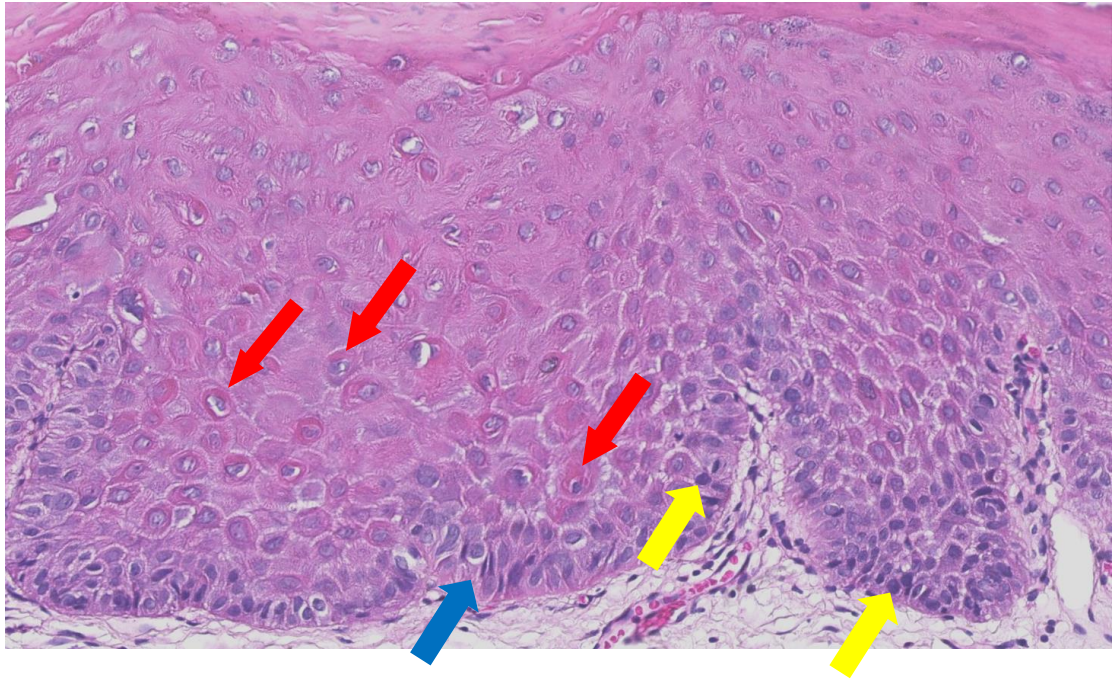


Fig 4.

