

NO. 095 Lichen planus, erosive and reticular type

<ul style="list-style-type: none"> ➤ 低倍下，可見表皮與結締組織間有一個黑色的區域為 lymphocyte infiltrate，即 band-like lymphocyte infiltrate。 ➤ 這些 lymphocytes 會攻擊其上方的表皮細胞，導致 basal cell degeneration，所以 basement membrane 會消失。 ➤ 在 basal cell layer 有 hydropic degeneration (vacuolar change)。 ➤ 有時甚至整個表皮脫落形成 ulcer，此時稱 erosive type。 ➤ 表皮受到發炎細胞刺激，可能會有 orthokeratosis 或 parakeratosis，因此在 reticular type 臨床上會看到白色網狀線條，稱 Wickham striae。 	<p>標記重點：</p> <ol style="list-style-type: none"> 1. Erosive area (ulcer) (Fig. 1 yellow ↑) 2. Reticular area (hyperparakeratosis) (Fig. 1 green ↑) 3. Subepithelial cleft (Fig. 1 blue ↑) 4. Band-like lymphocyte infiltrate (Fig. 1 red line & Fig. 2 red ★) 5. Basal cell layer degeneration (Fig. 2 green ↑)
----------------------------------------------------------------------------------------------------------------------------------------------------------------------------------------------------------------------------------------------------------------------------------------------------------------------------------------------------------------------------------------------------------------------------------------------------------------------	-----------------------------------------------------------------------------------------------------------------------------------------------------------------------------------------------------------------------------------------------------------------------------------------------------------------------------------------------------------------------

Fig. 1

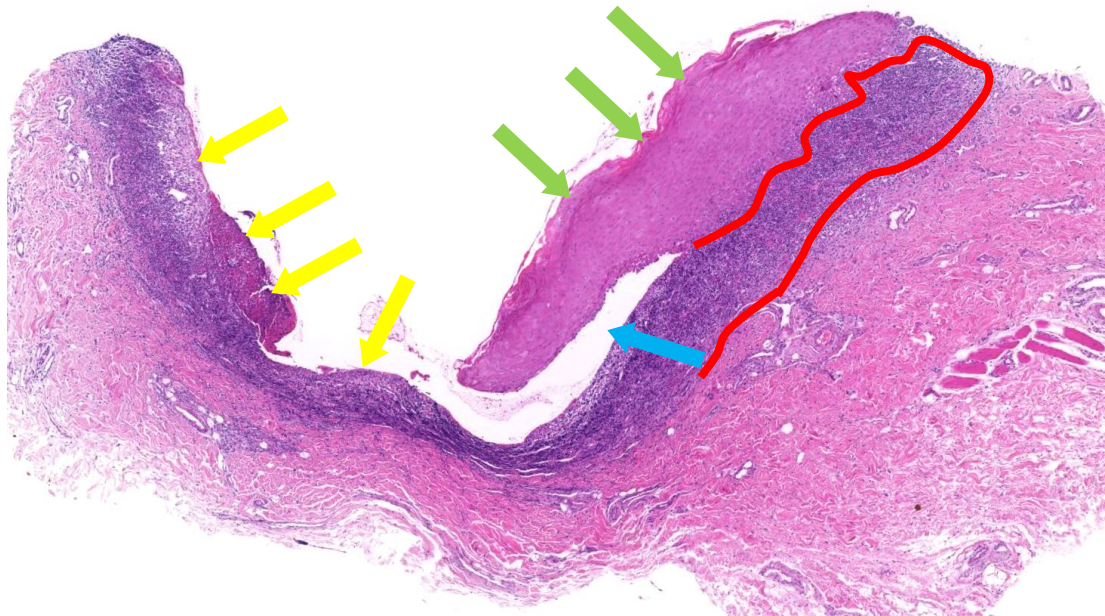


Fig. 2

