

NO. 080 Mucocele

<ul style="list-style-type: none">➤ 可見到 epithelium 下方有一 mucin pooling。周圍有 fibrous stroma、muscle、minor salivary gland➤ Mucin pooling 裡面有吃了 mucin，而形狀變得圓胖的 foamy histiocyte➤ Mucin pooling 的周邊可見有像 granulation tissue 的組織，且有血管的增生。➤ 待溢出的 mucin 被 foamy histiocytes 清除乾淨，granulation tissue 會長滿整個原先的 mucin pooling 處，使組織修復再生。	<p>標記重點：</p> <ol style="list-style-type: none">1. Covering epithelium (Fig. 1 red ↑)2. Mucin pooling (Fig. 1 blue ↑)3. Minor salivary gland (Fig. 1 yellow ↑)4. Histiocyte (foamy cell) (Fig. 3 red ↑)5. Granulation tissue (Fig. 2 green ↑)
---------------------------------------------------------------------------------------------------------------------------------------------------------------------------------------------------------------------------------------------------------------------------------------------------------------------------------------------------------------------	--------------------------------------------------------------------------------------------------------------------------------------------------------------------------------------------------------------------------------------------------------------------------------------------------

Fig. 1

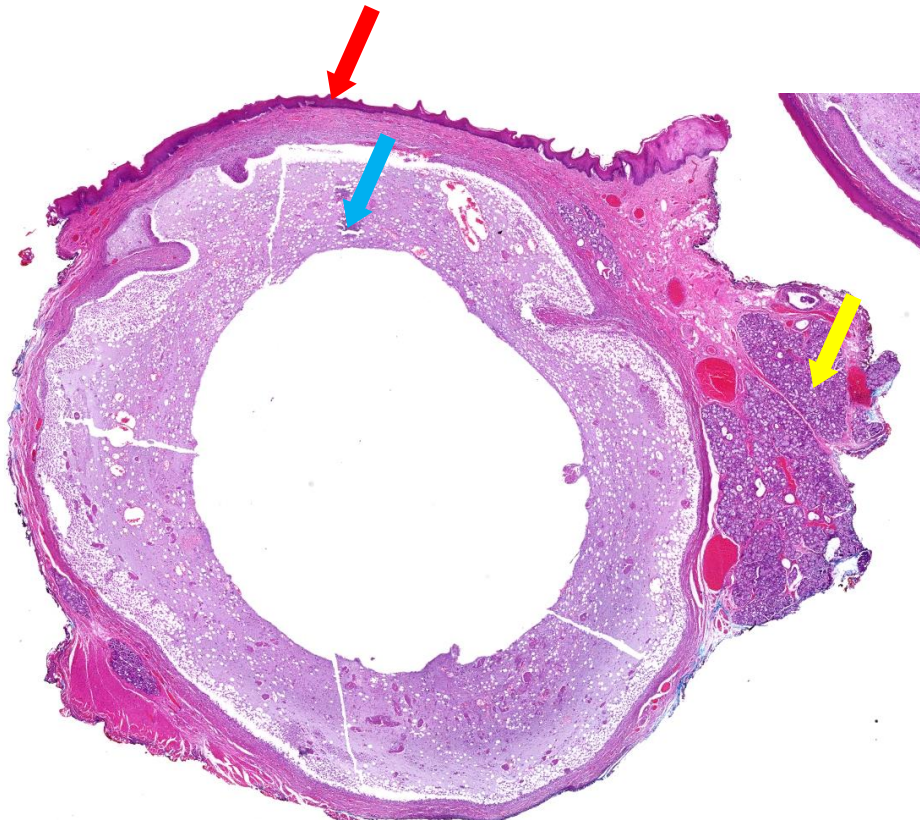

Fig. 2

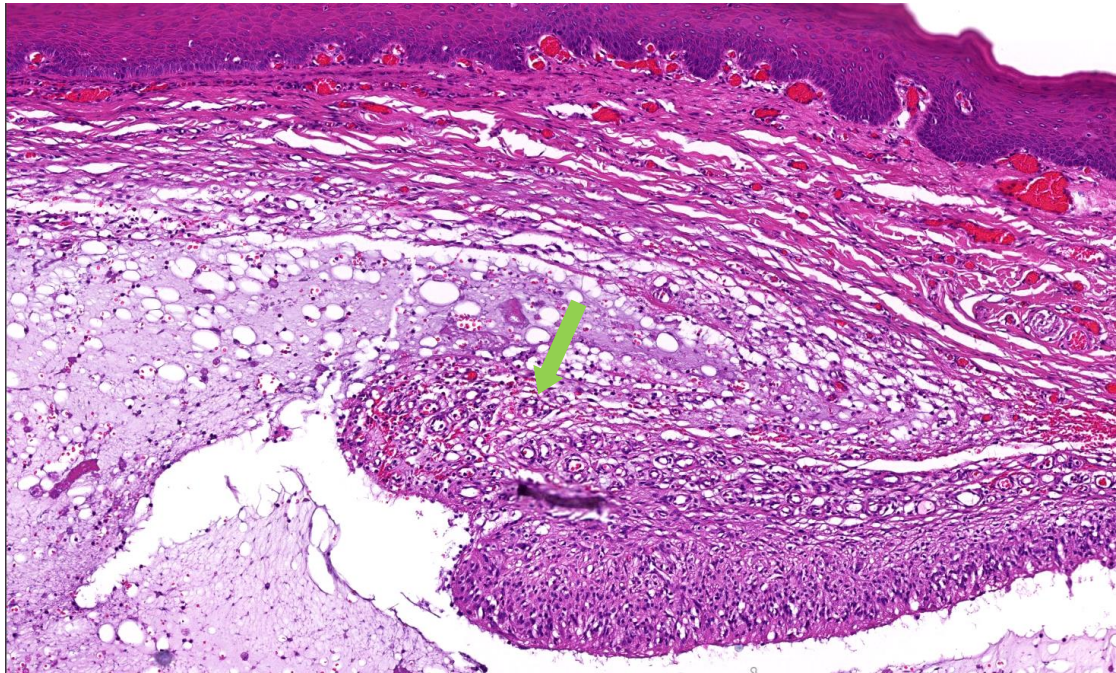


Fig. 3

