

NO. 070 Epidermoid cyst

<ul style="list-style-type: none"> ➤ Cyst 的三個要件：cystic wall、lumen / cavity、lining epithelium ➤ Cyst wall 外有正常的 skin (Fig. 1 black ↑) · dermis 中可見皮膚衍生物 (skin appendage) 中的 sebaceous gland (Fig. 1 white ↑) 。 ➤ Cystic wall 上沒有皮膚衍生物 (skin appendage) ➤ Lining epithelium 被擠壓的很扁 (atrophy) · 有 hyperorthokeratosis ➤ Lumen 內有 keratin 	<p>標記重點：</p> <ol style="list-style-type: none"> 1. Cyst 三要素：cystic wall (Fig. 1 green ↑) · lumen / cavity (Fig. 1 yellow ↑) · lining epithelium (Fig. 1 blue ↑) 2. Lining epithelium：orthokeratinized stratified squamous epithelium (Fig. 2 blue ↑) 3. Keratin in lumen (Fig. 2 yellow ↑) 4. Cyst wall 上沒有 Skin appendage：hair follicle · sweat gland · sebaceous gland
--	--

Fig. 1

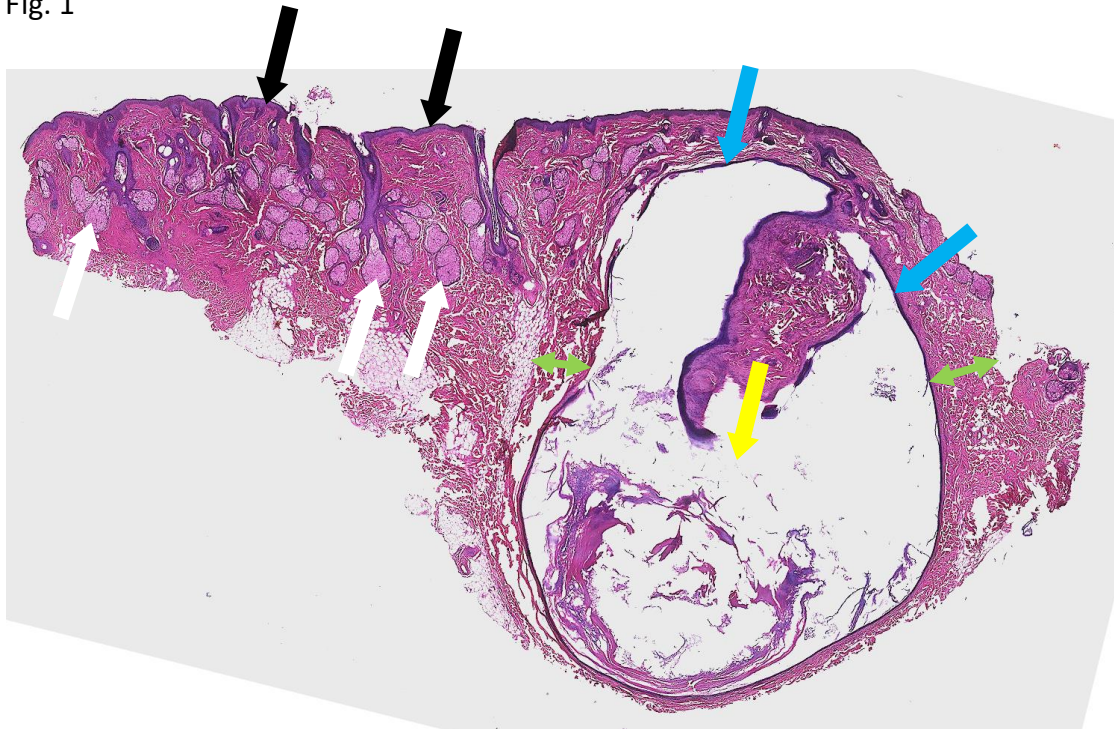


Fig. 2

