

## NO. 054 Histoplasmosis

<ul style="list-style-type: none"><li>➤ 此疾病為一種侵襲性黴菌感染。</li><li>➤ 低倍下可見有著大量發炎細胞的 granulation tissue (Fig. 1 red ↑)及殘餘的 minor salivary gland (Fig. 1 blue ↑)。</li><li>➤ Granulation tissue 部分於高倍下可見大量 histiocytes 與 chronic inflammatory cells。</li><li>➤ 此外，可見大量穿插在發炎細胞中的 organisms of <i>Histoplasma capsulatum</i>。</li></ul>	<p>標記重點：</p> <ol style="list-style-type: none"><li>1. Organisms of <i>Histoplasma capsulatum</i> (Fig. 2,3 red ↑)</li><li>2. Histiocyte (Fig. 2 yellow ↑)</li><li>3. Lymphocyte (Fig. 2 green ↑)</li></ol>
--	--

Fig. 1

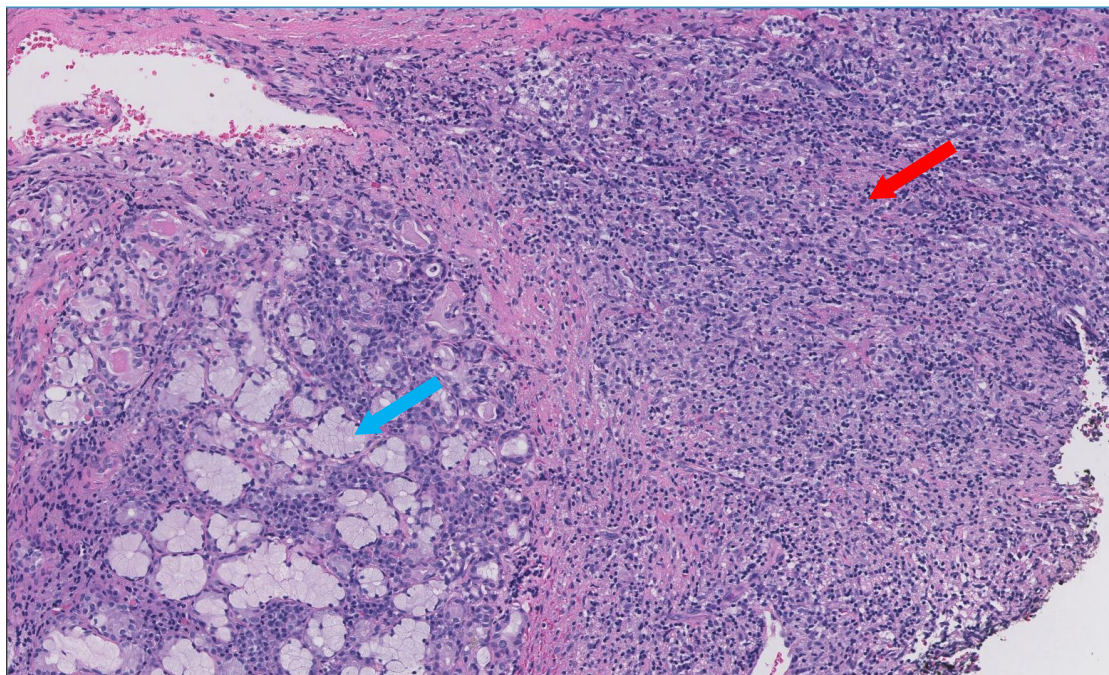


Fig. 2

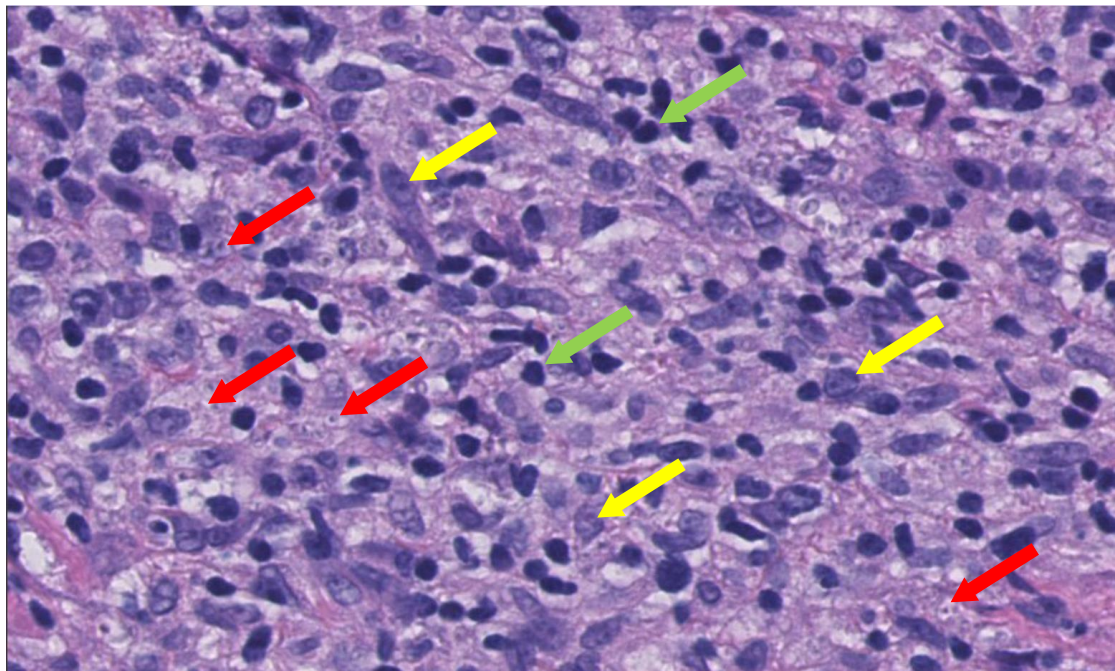


Fig. 3

