

NO. 019 Congenital epulis

<ul style="list-style-type: none">➤ Epulis 泛指口腔的腫塊跟突起。➤ 下方的結締組織為重點，其間充滿 granular cell，在高倍下，cytoplasm 內有很多 granule，且 cell nucleus 偏向一側。(Fig. 2 red ↑)➤ 雖然都是由 granular cells 構成的病灶，但 granular cell tumor 上方的上皮呈現 pseudo-epitheliomatous hyperplasia；而 congenital epulis 表皮很薄且有 atrophy of rete peg 的現象。(Fig. 1 yellow line)	<p>標記重點：</p> <ol style="list-style-type: none">1. Large, round cells with abundant granular, eosinophilic cytoplasm and round to oval, lightly basophilic nuclei (Fig. 2 red ↑)2. Atrophy of the rete ridge (Fig. 1 yellow line)
---	---

Fig. 1

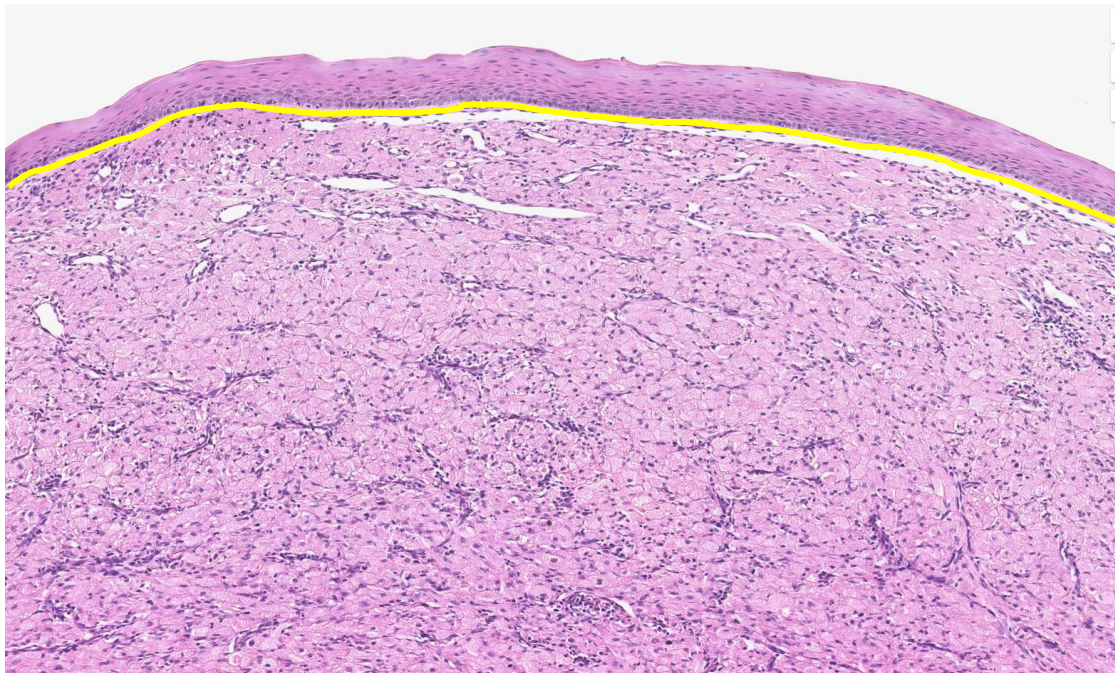


Fig. 2

