NO. 009　Squamous cell carcinoma (moderately-differentiated)

➢ 表皮層(epithelium)增厚(acanthosis)，原本規則的表皮變不規則，而增生的表皮細胞形成一團一團的 tumor islands (Fig. 1&2 red↑)向下侵犯至小唾液腺(Fig. 1 green↑)。 ➢ 可見周邊的上皮也有明顯的 dysplastic change。程度可達 carcinoma in situ (Fig. 1 blue↑)。 ➢ 與上片相比其 intercellular bridge 較不明顯，有些地方 tumor cells 間的連結變得較不緊密(acantholysis)。 ➢ 因分化較差，所以 keratin 生成較少，而 tumor cell 的特徵：pleomorphism、hyperchromatism、N/C ratio 增加、abnormal mitosis、individual cell keratinization 與前片相同。 ➢ Tumor islands 中出現 necrosis。(Fig. 6 white↑) ➢ 周邊可見 tumor cells 侵犯至血管內。(Fig. 5 red↑)	標記重點： 1. Tumor islands (Fig. 1 red↑) 2. Dysplasia: a. Pleomorphism (型態不一) b. hyperchromatism (Fig. 3 yellow↑) c. N/C ratio 增加(Fig. 3 green↑) d. abnormal mitosis (Fig. 3 blue↑) e. Individual cell dyskeratosis (Fig. 4 red↑) 3. Intravascular invasion (Fig. 5 red↑) 4. Tumoral necrosis (Fig. 6 white↑)

Fig. 1

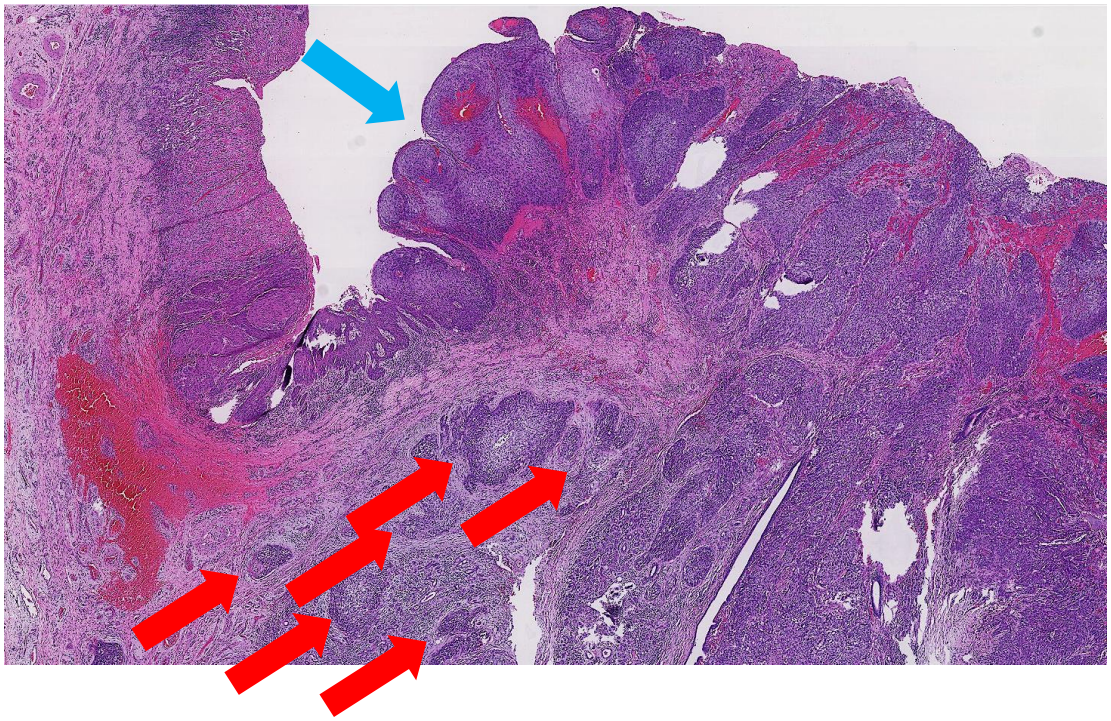

Fig. 2

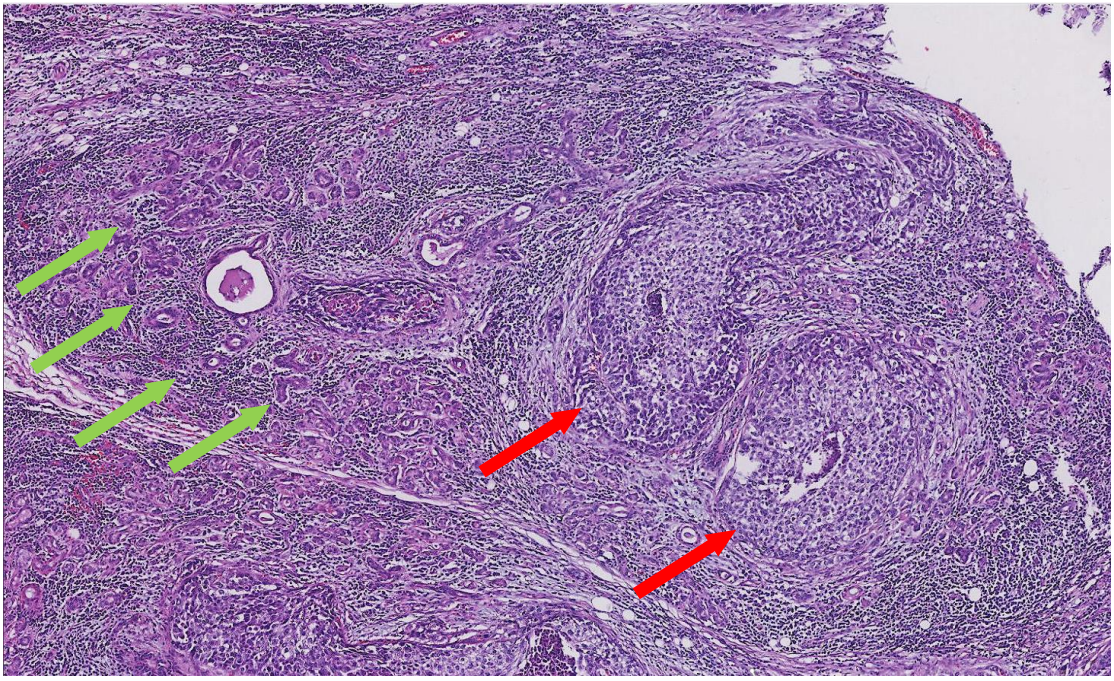

Fig. 3

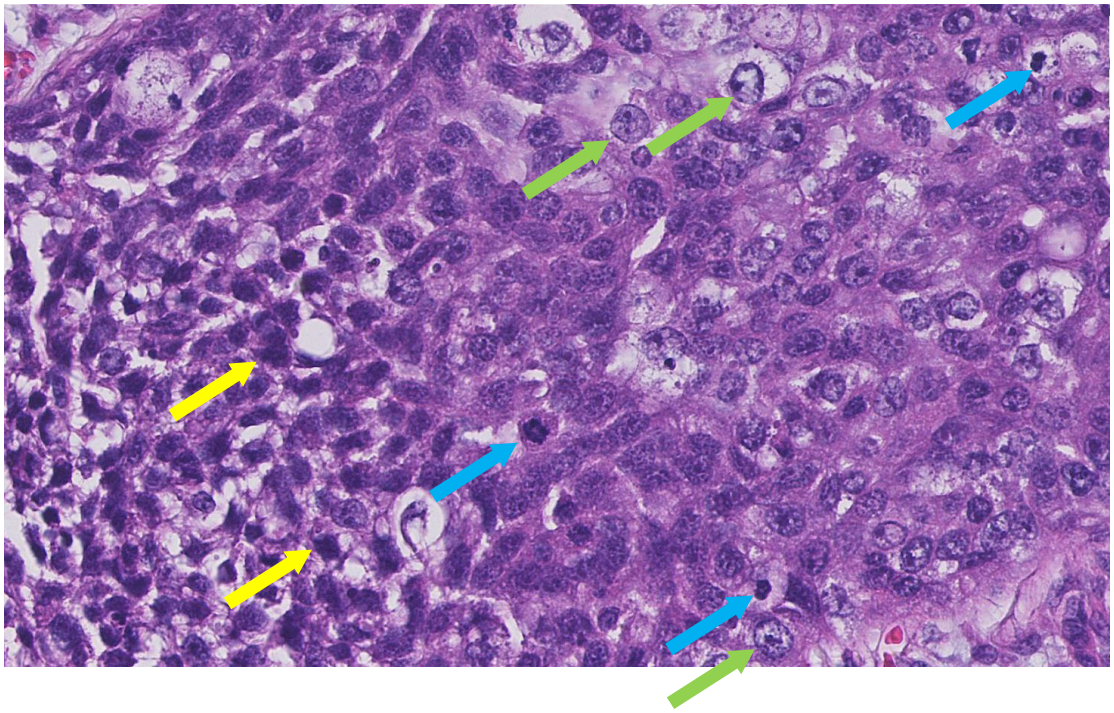

Fig. 4

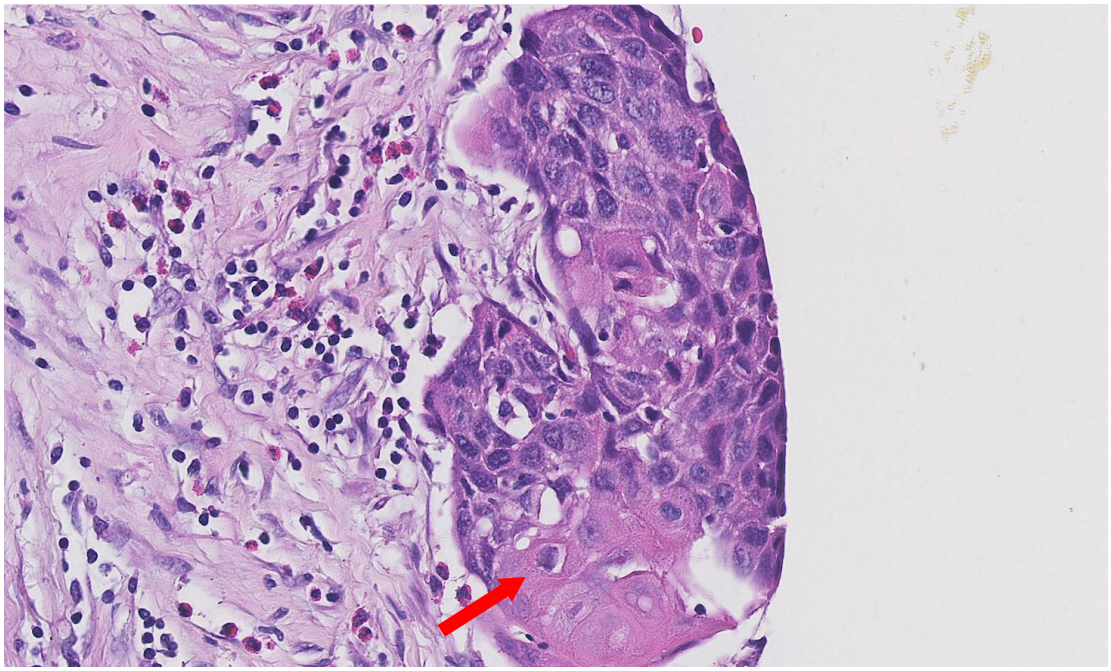

Fig. 5

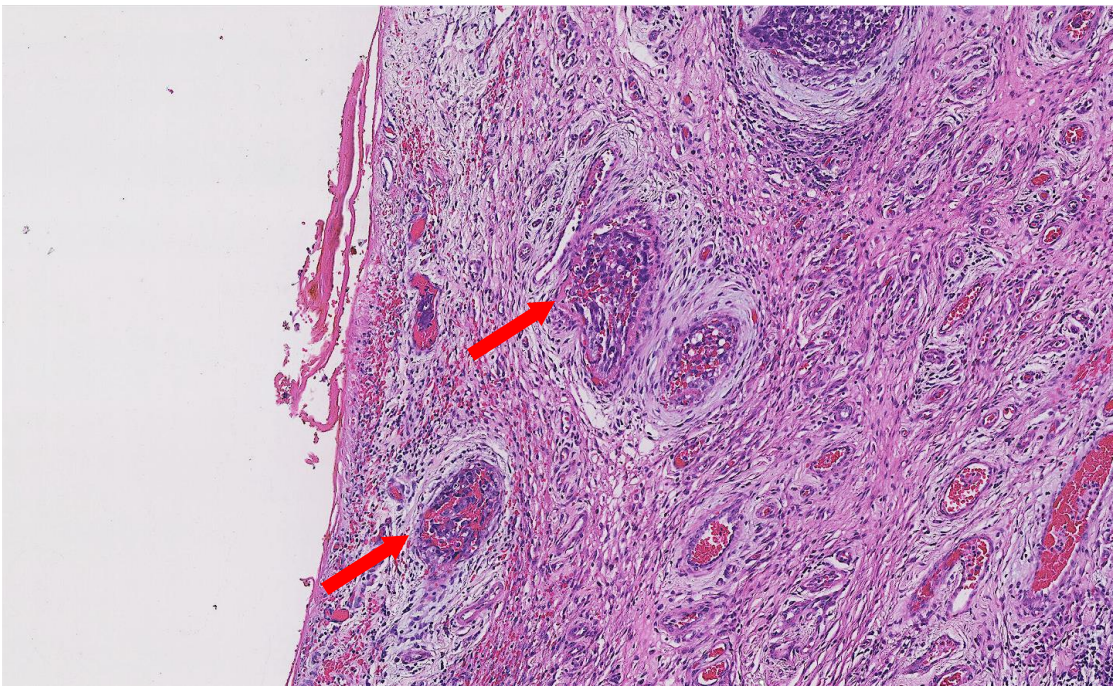
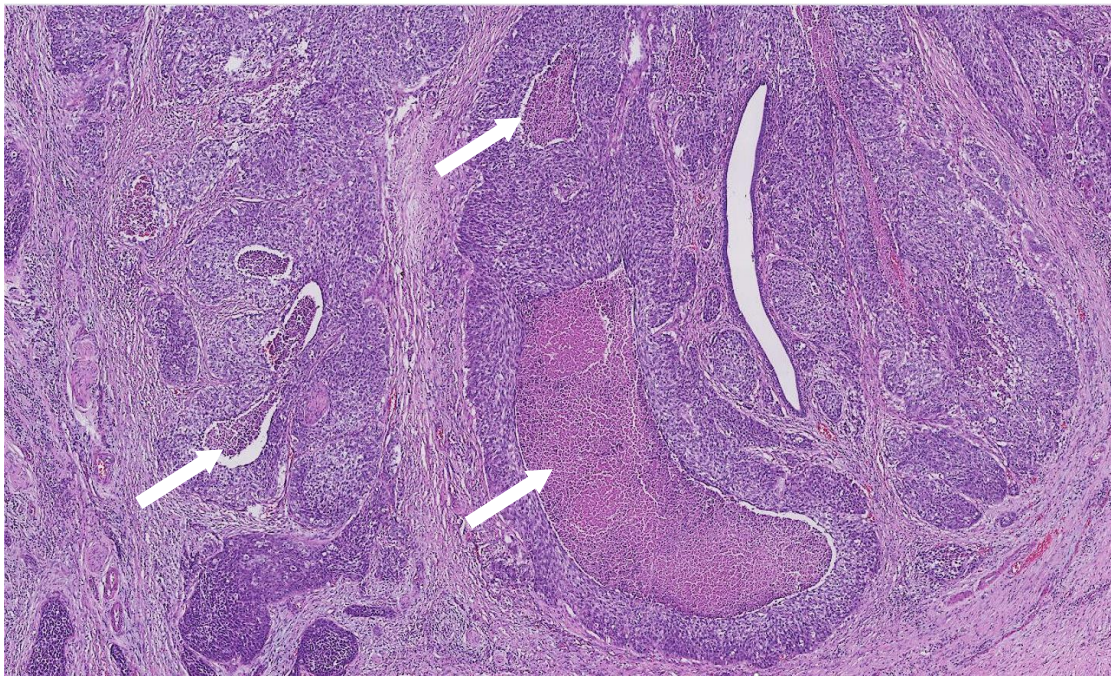
Fig. 6