

NO. 045 Sequestrum

<ul style="list-style-type: none">➤ Necrotic bone · 失去活性的骨頭 (nonvital bone)➤ 骨頭的 lacuna 內沒有 osteocyte · 也沒有正常的 bone marrow tissue(因為都已經 necrotic)➤ Trabecular margin irregular · 有 peripheral resorption 。➤ Necrotic debris 在 bone 周圍 · 是由 bacterial colonization 和 inflammatory cell 所構成 。	<p>標記重點：</p> <ol style="list-style-type: none">1. Bone trabeculae with irregular margin (Fig. 1,2,3 blue ↑)2. Lacuna without osteocyte (Fig. 2 red ↑)3. Bacterial colonization (Fig. 2, 3 yellow ↑)4. Inflammatory cells (Fig. 2,3 green ↑)
--	--

Fig.1

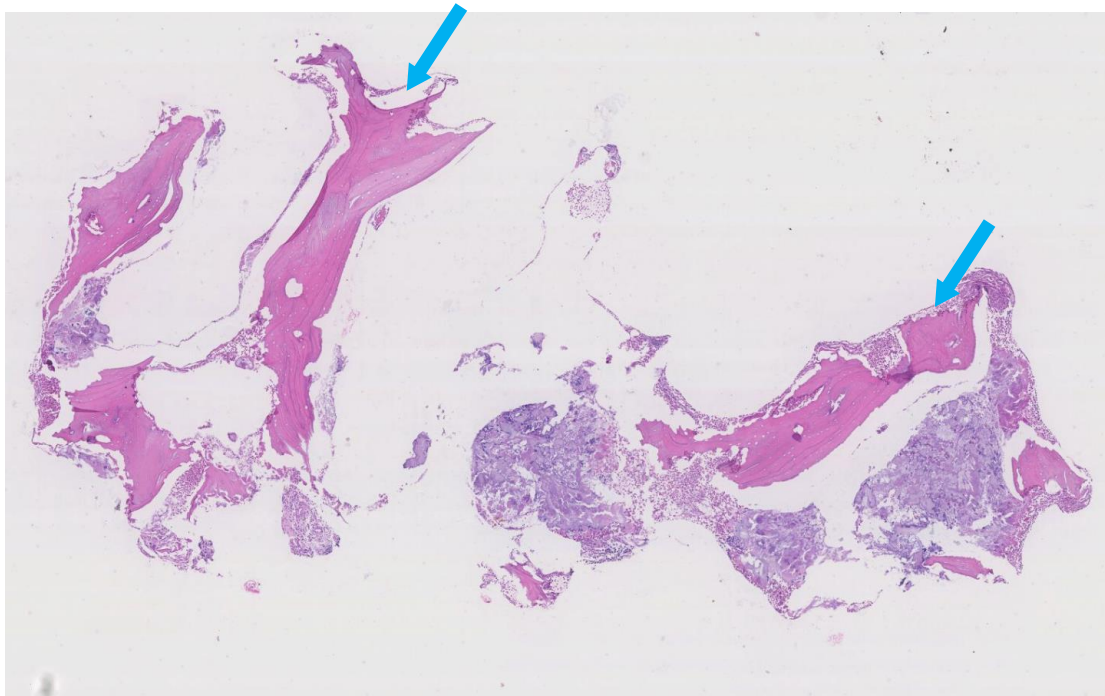


Fig. 2

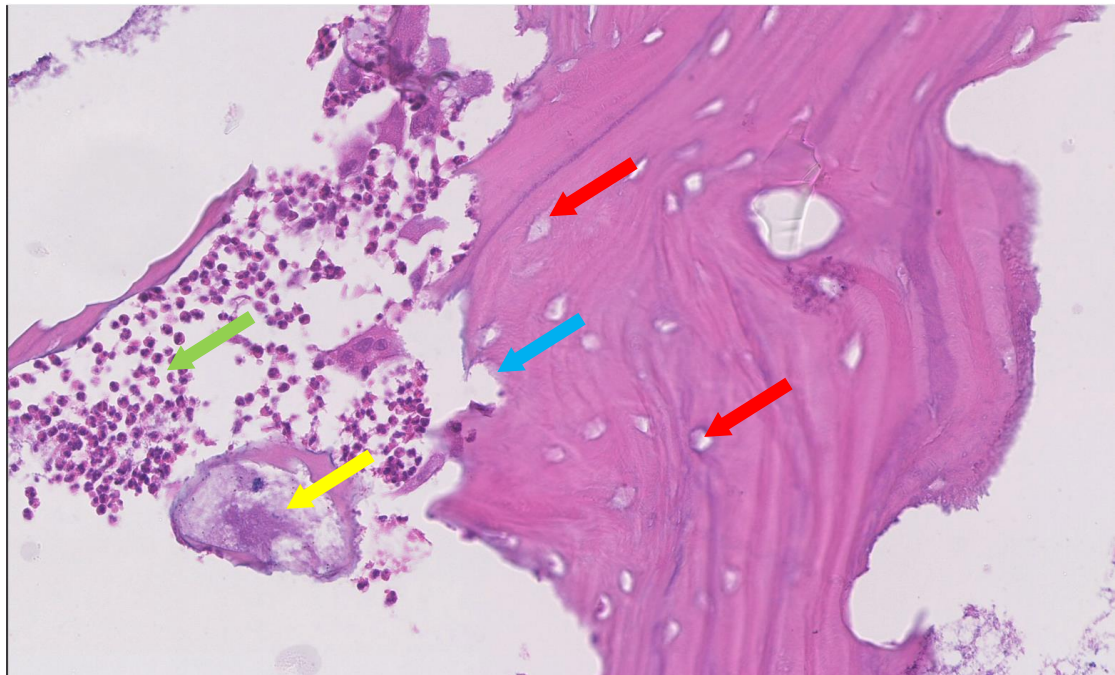


Fig.3

