

NO. 039 Calcifying epithelial odontogenic tumor

<p>➤ 此 tumor 主要由三要素所構成：</p> <p>a. Epithelial cells: 增生的 odontogenic epithelium，其以 sheets、islands 或 cords 的形態排列。細胞呈現多角形(polyhedral)，伴隨 clear or eosinophilic cytoplasm。</p> <p>b. Matrix (amyloid material): 腫瘤內可見圓形或不規則狀的粉紅色均質物質 (eosinophilic hyaline material)。</p> <p>c. Calcification: 會有鈣化物的出現。有些鈣化物呈現濃染同心圓狀(basophilic concentric layers)，稱為 Liesegang rings。這些鈣化物會彼此融合，形成 large、complex masses (Fig. 1 black ↑)。</p> <p>➤ 本片中還可見到一個牙根，其被腫瘤(Fig. 2 red ★)壓迫形成牙根吸收。</p>	<p>標記重點：</p> <ol style="list-style-type: none"> 1. Polyhedral epithelial cells (Fig. 1 green ↑) 2. Amyloid deposits (Fig. 1 red ↑) 3. Liesegang rings (Fig. 1 blue ↑) 4. Masses of calcification (Fig. 1 yellow ★; Fig. 2 yellow ↑) 5. External root resorption by tumor (Fig. 2 dot line)
---	---

Fig. 1

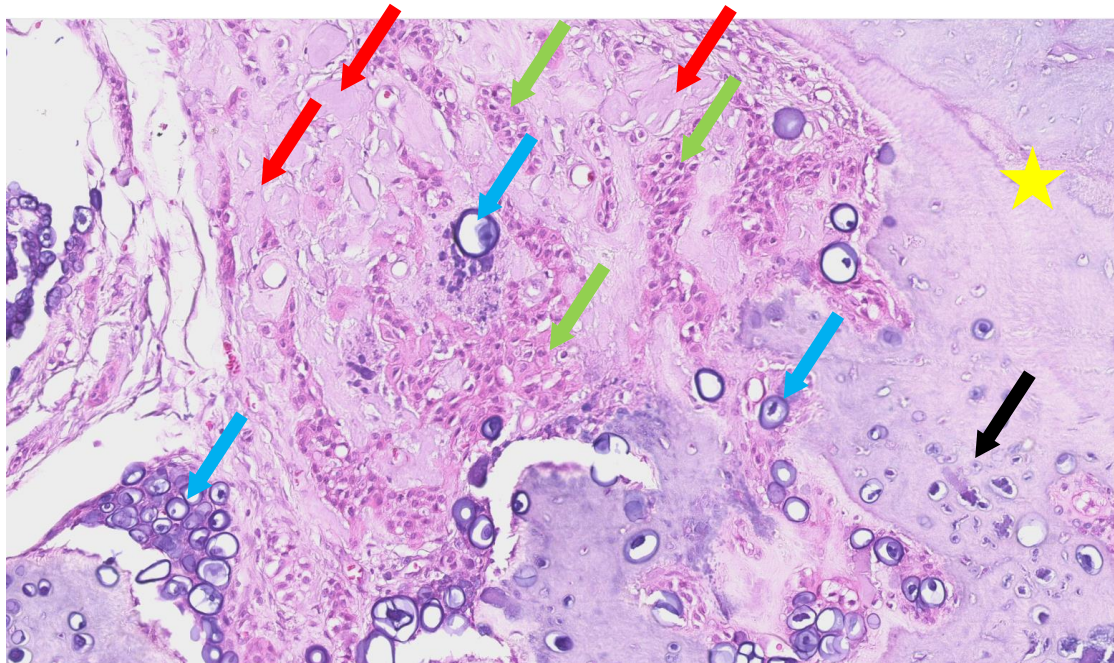


Fig.2

