NO. 012　Basal cell carcinoma

➢ 低倍下，腫瘤以 islands、nests、cords 的型態往下方 dermis 侵犯(Fig. 1 red↑)。周圍可見皮脂腺(Fig. 1 green↑)、毛囊(Fig. 1 yellow↑)因此可知其為皮膚。 ➢ 表面覆蓋的 epidermis(Fig. 1 black↑)常有 ulceration(Fig. 1 blue↑)的情形。 ➢ 高倍下，腫瘤由型態單一、深染、似基底細胞(basaloid cells)所構成(Fig. 2 yellow★)。其有增大且濃染的細胞核(enlarged hyperchromatic nuclei)、不明顯的核仁(inconspicuous nucleoli)及少量的細胞質(scant cytoplasm)。 ➢ Tumor islands 周圍可見腫瘤細胞呈現平行排列(palisading) (Fig. 2 red↑)。 ➢ 偶而可見腫瘤內出現 keratin production (Fig. 3 red↑)或 sebaceous differentiation。	標記重點： 1. Tumor islands (Fig. 1 red↑) 2. Ulceration (Fig. 1 blue↑) 3. Hair follicle (Fig. 1 yellow↑) 4. Sebaceous gland (Fig. 1 green↑) 5. Palisading of the peripheral cells (Fig. 2 red↑) 6. Keratin production (Fig. 3 red↑) 7. Numerous mitotic figures (Fig. 2 blue↑)

Fig. 1

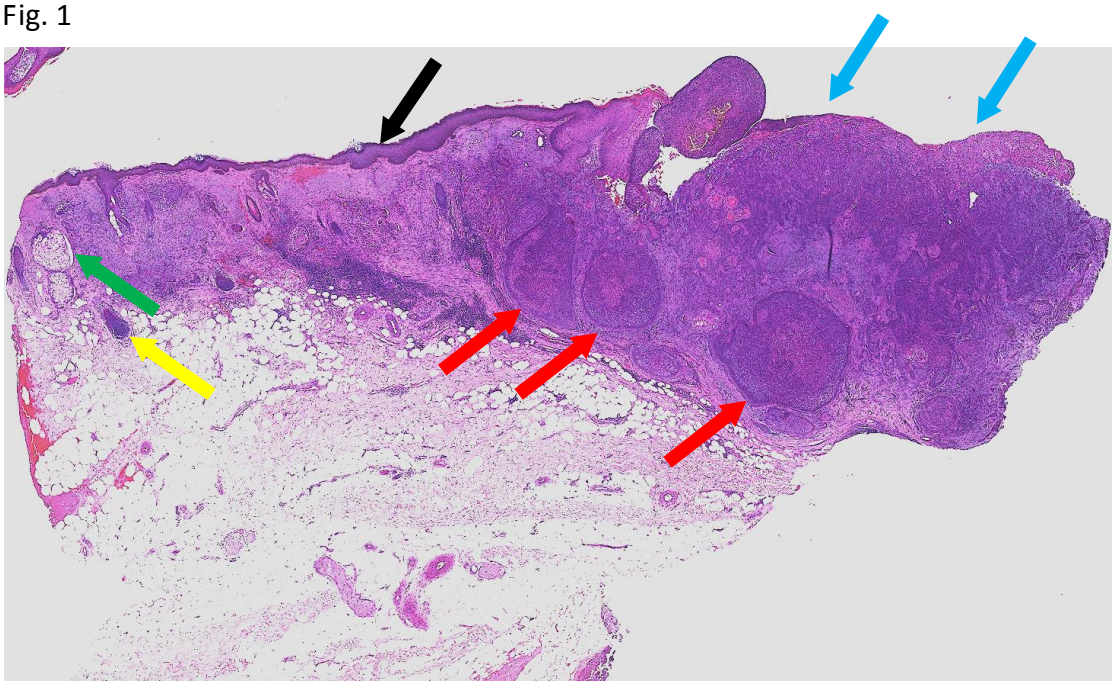

Fig. 2

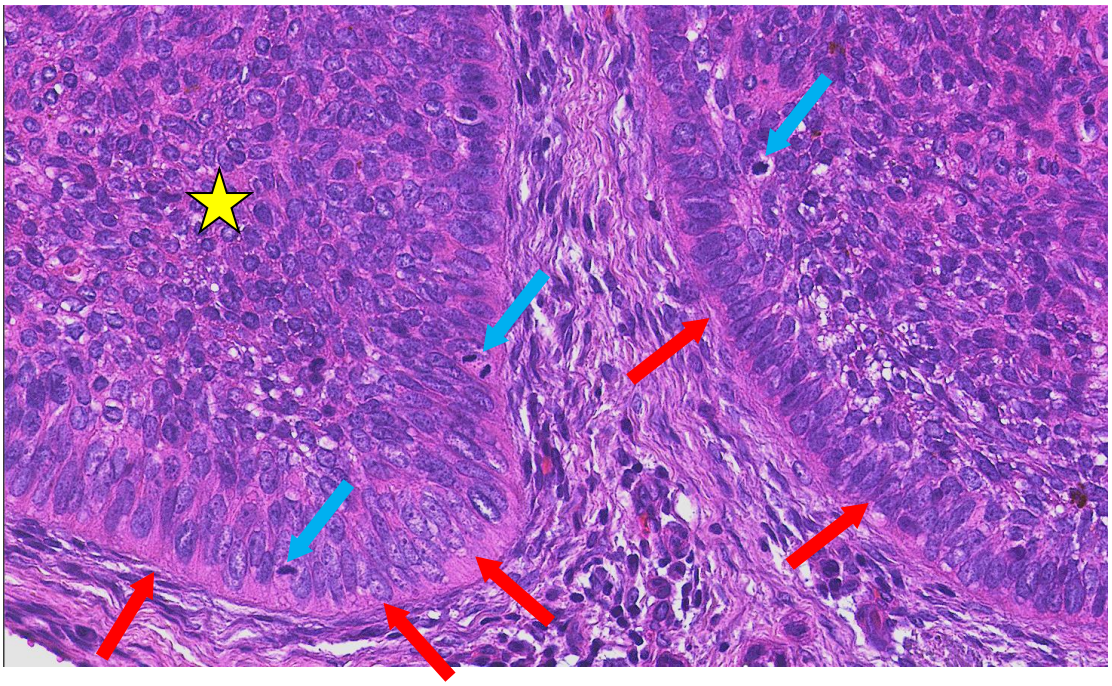
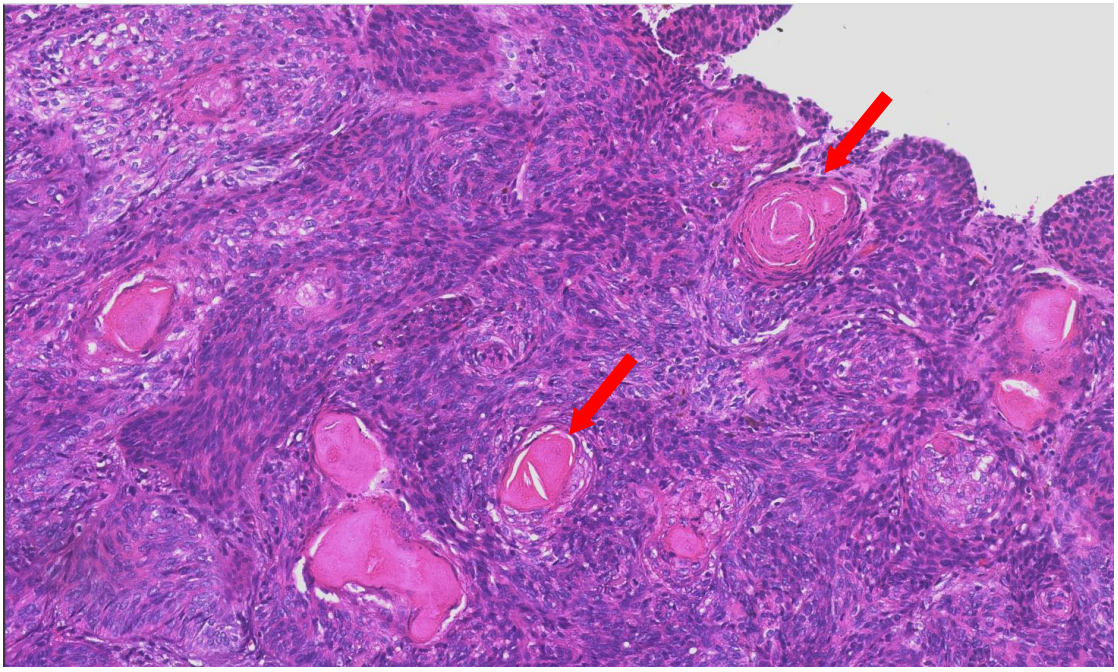
Fig. 3