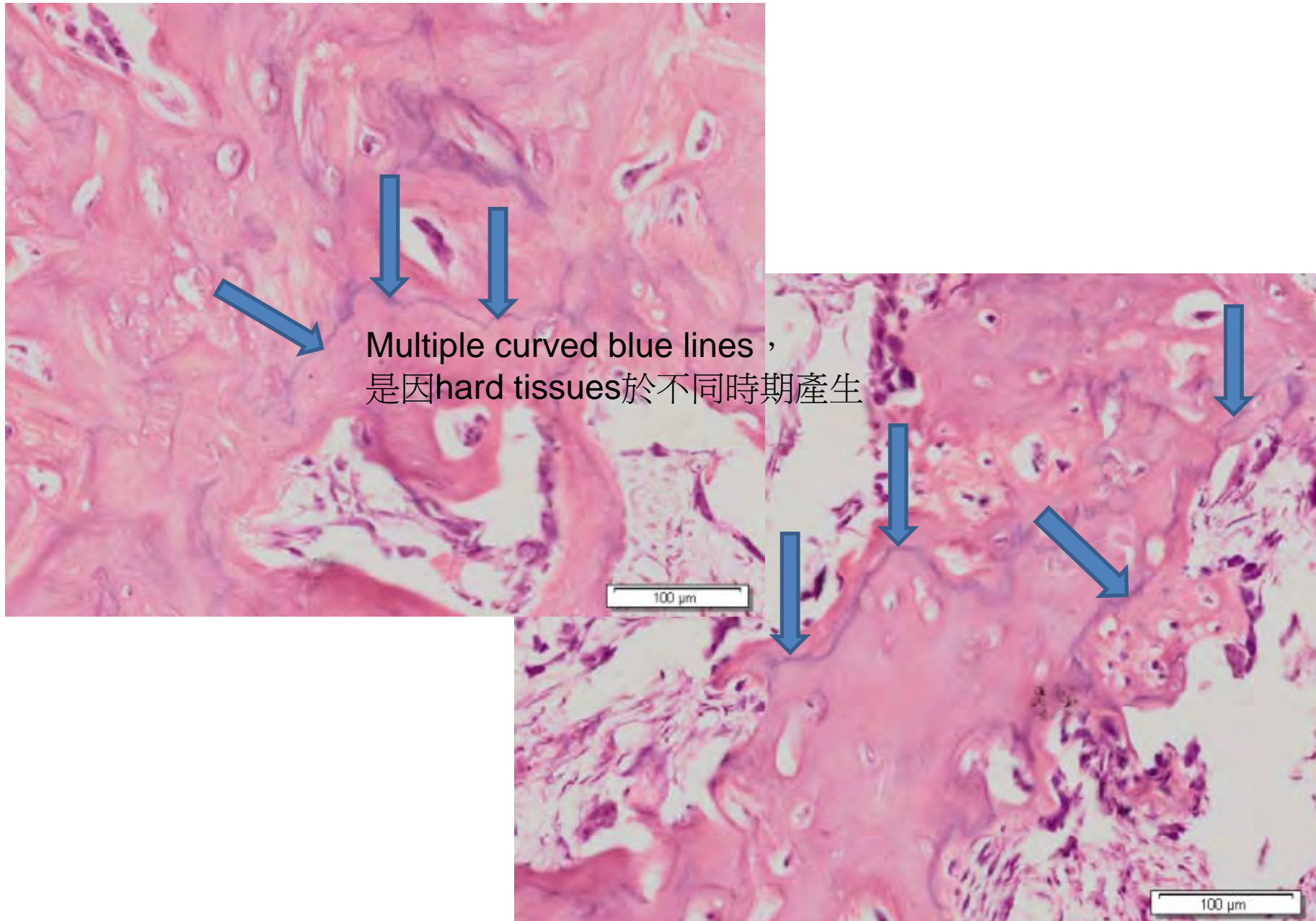


# 97年度口病實驗期中考

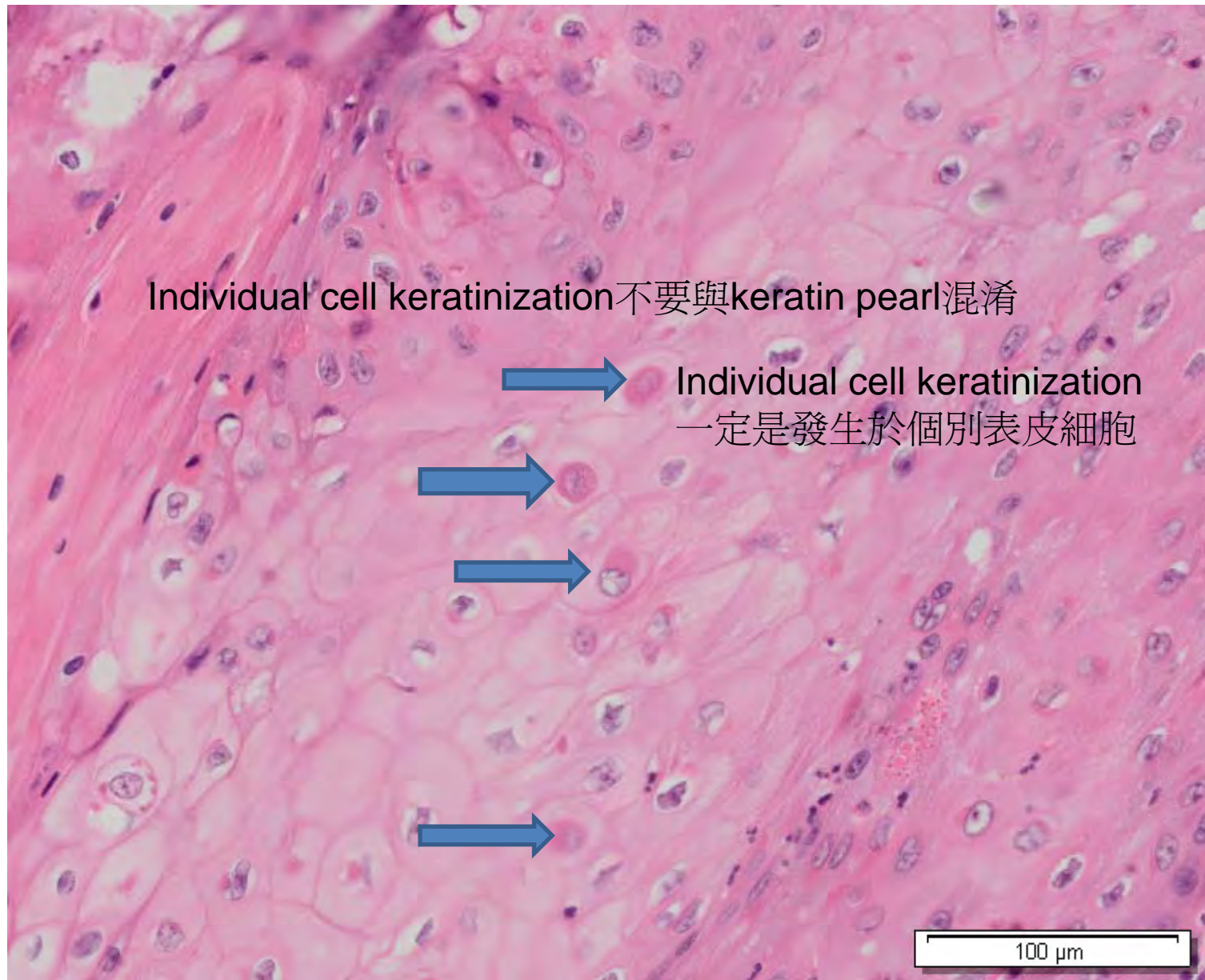
口腔病理特徵答案參考

A. 請從題目1-8中找出並標示 **Reversal line** 之病理特徵



<注意>請勿複製新投影片

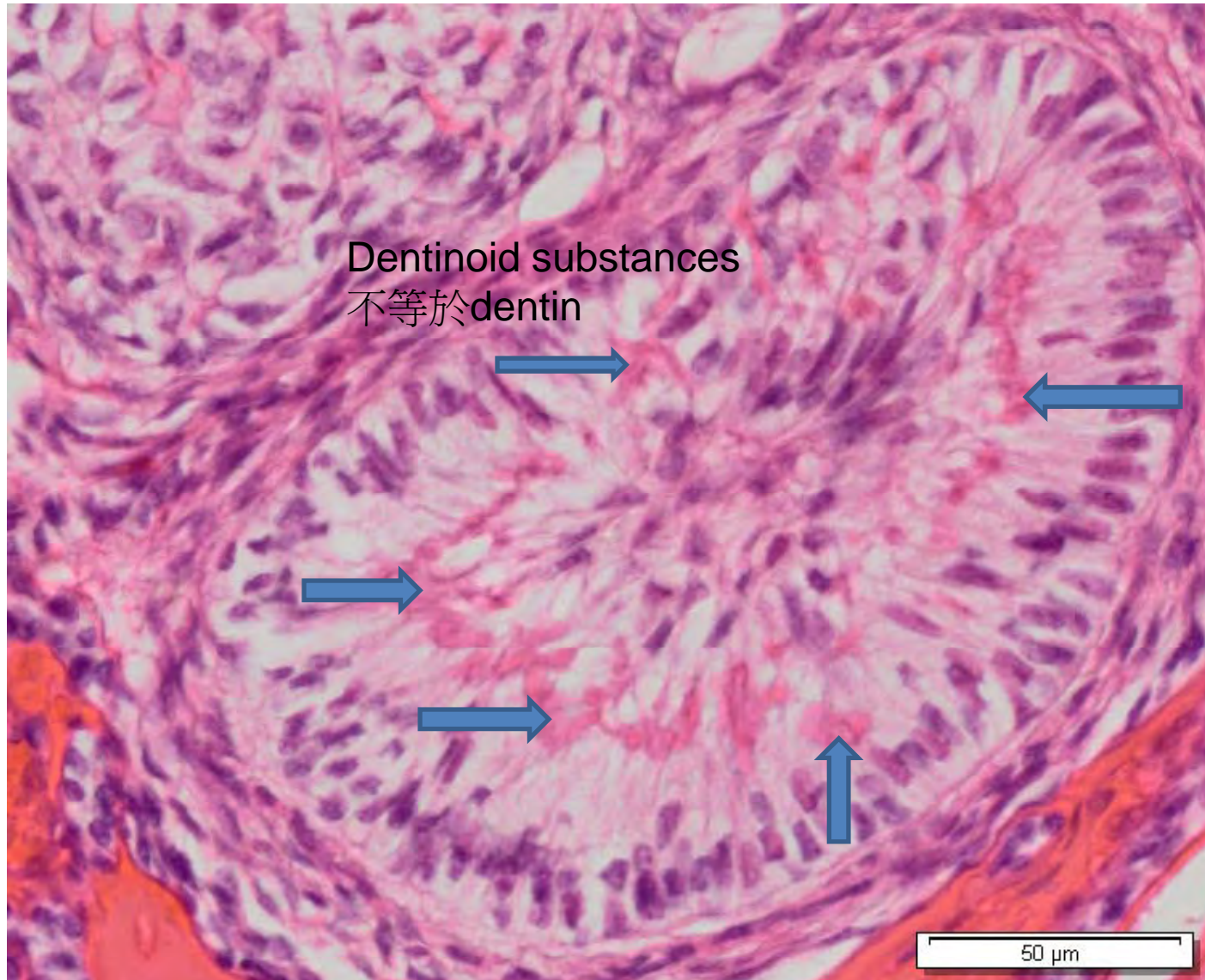
B. 請從題目1-8中找出並標示 Individual cell keratinization 之病理特徵



<注意>請勿複製新投影片

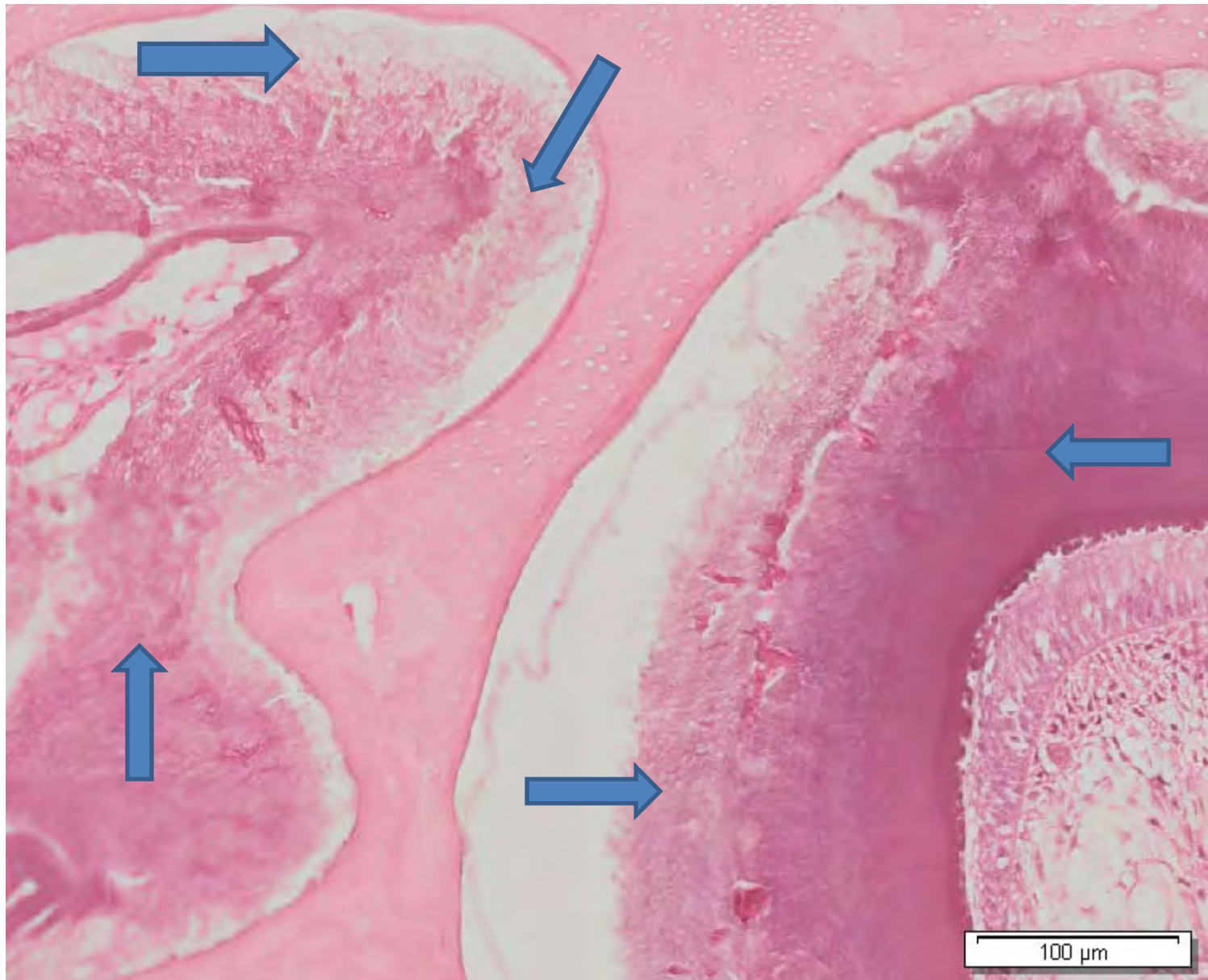

D. 請從題目1-8中找出並標示 Dentinoid substances 之病理特徵



<注意>請勿複製新投影片

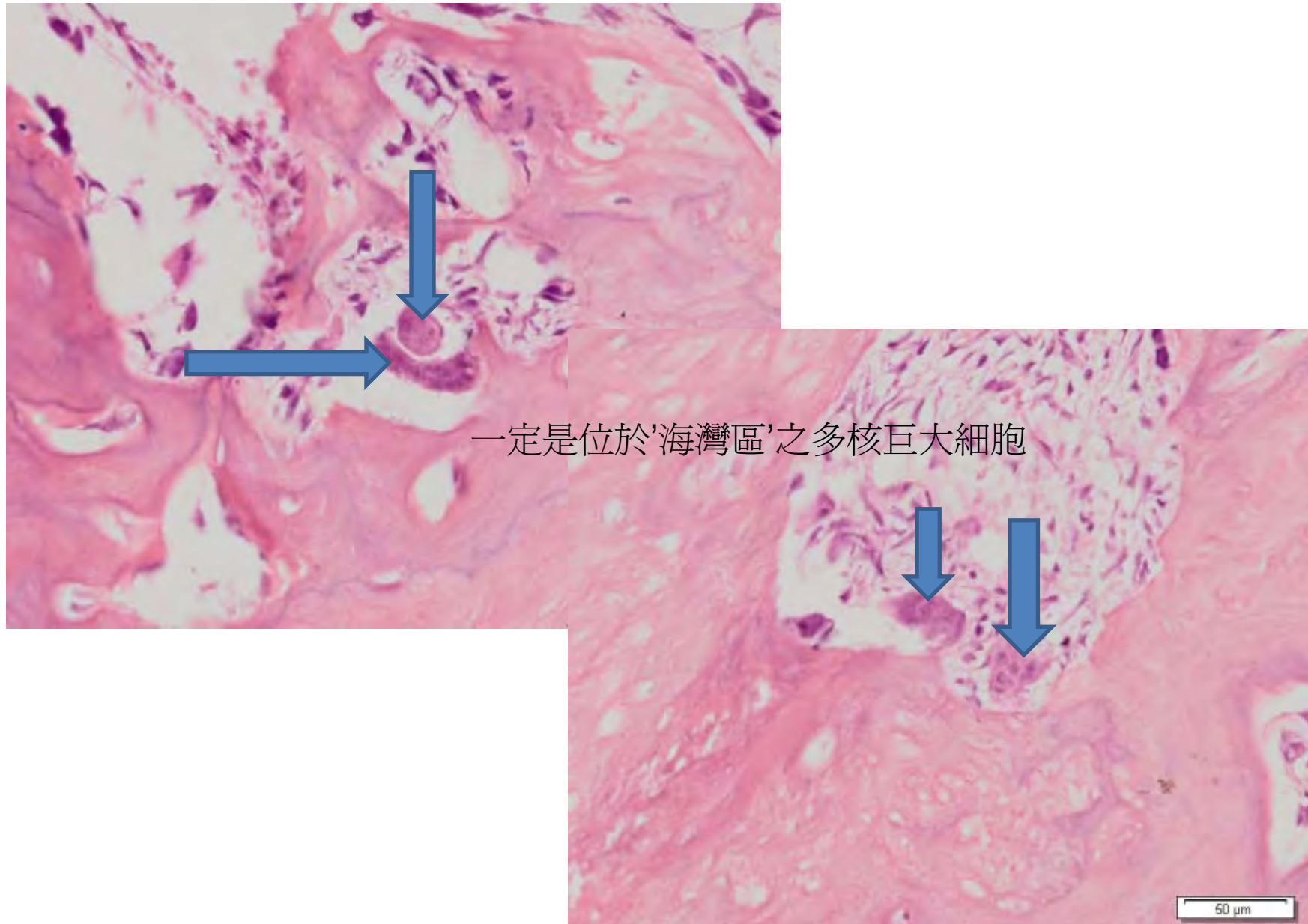
E. 請從題目1-8中找出並標示 Enamel matrix 之病理特徵



<注意>請勿複製新投影片

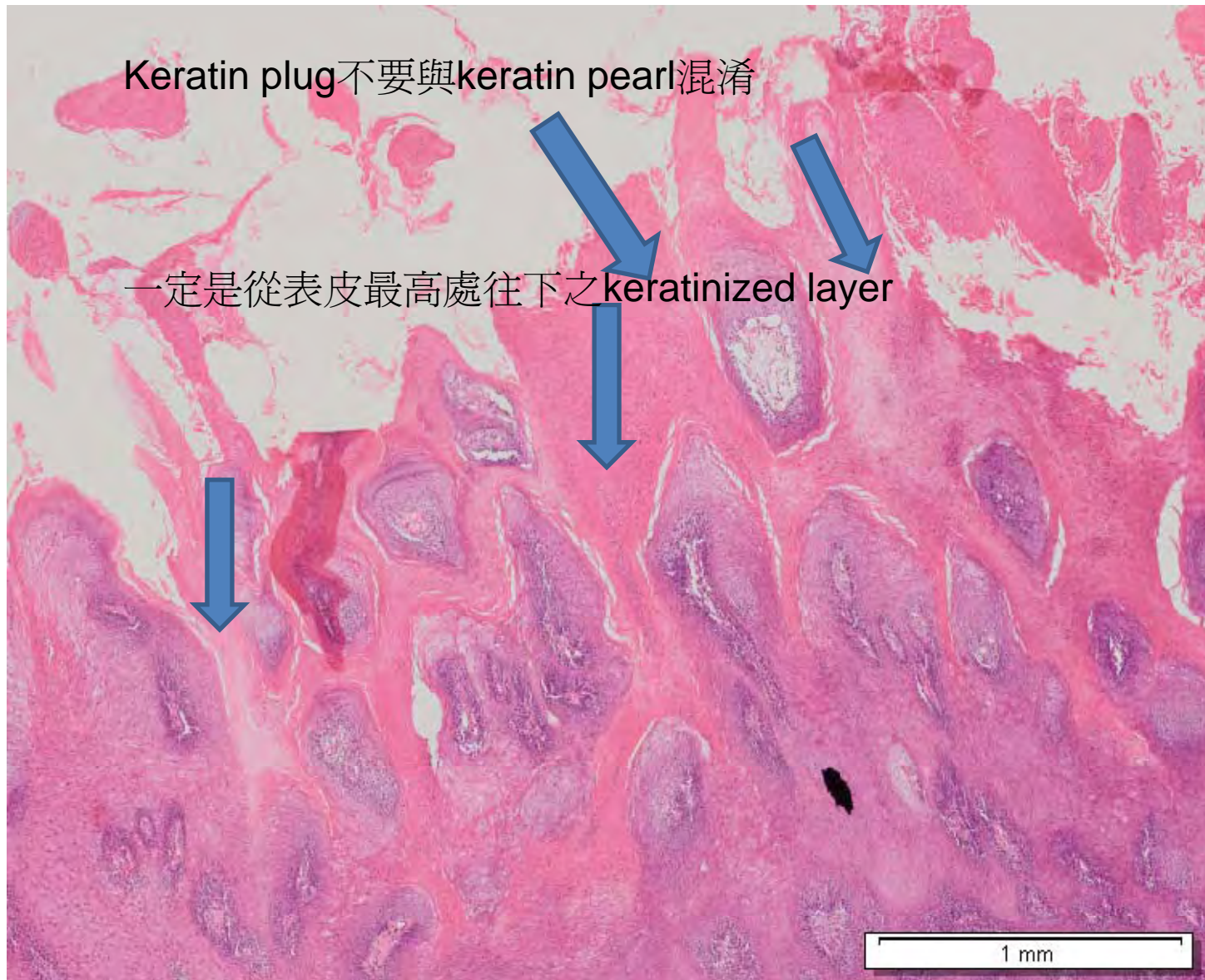


F. 請從題目1-8中找出並標示 Cementoclast 之病理特徵



<注意>請勿複製新投影片

G. 請從題目1-8中找出並標示 Keratin plug 之病理特徵

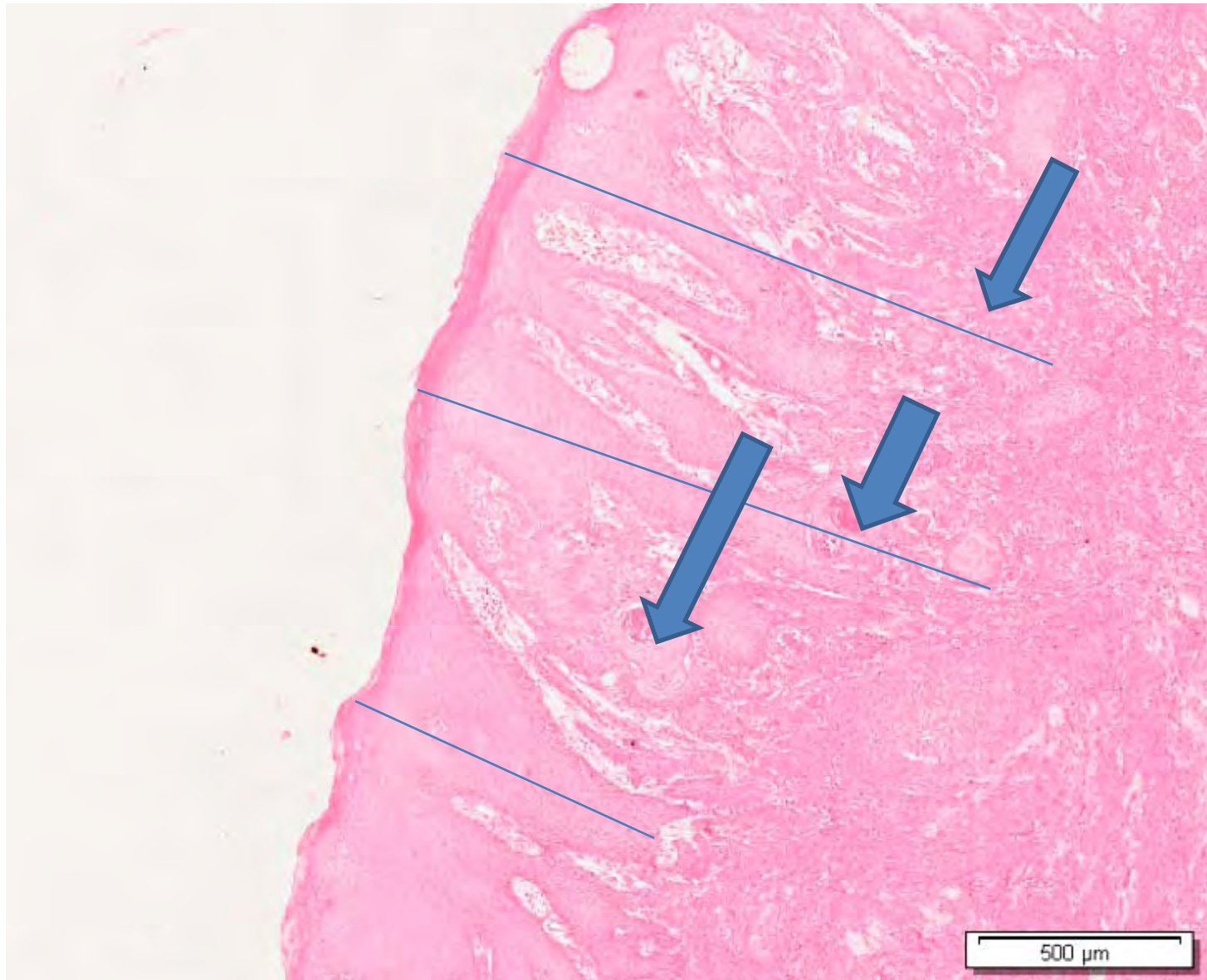


<注意>請勿複製新投影片



H. 請從題目1-8中找出並標示 Pseudoepithelial cell hyperplasia 之病理特徵

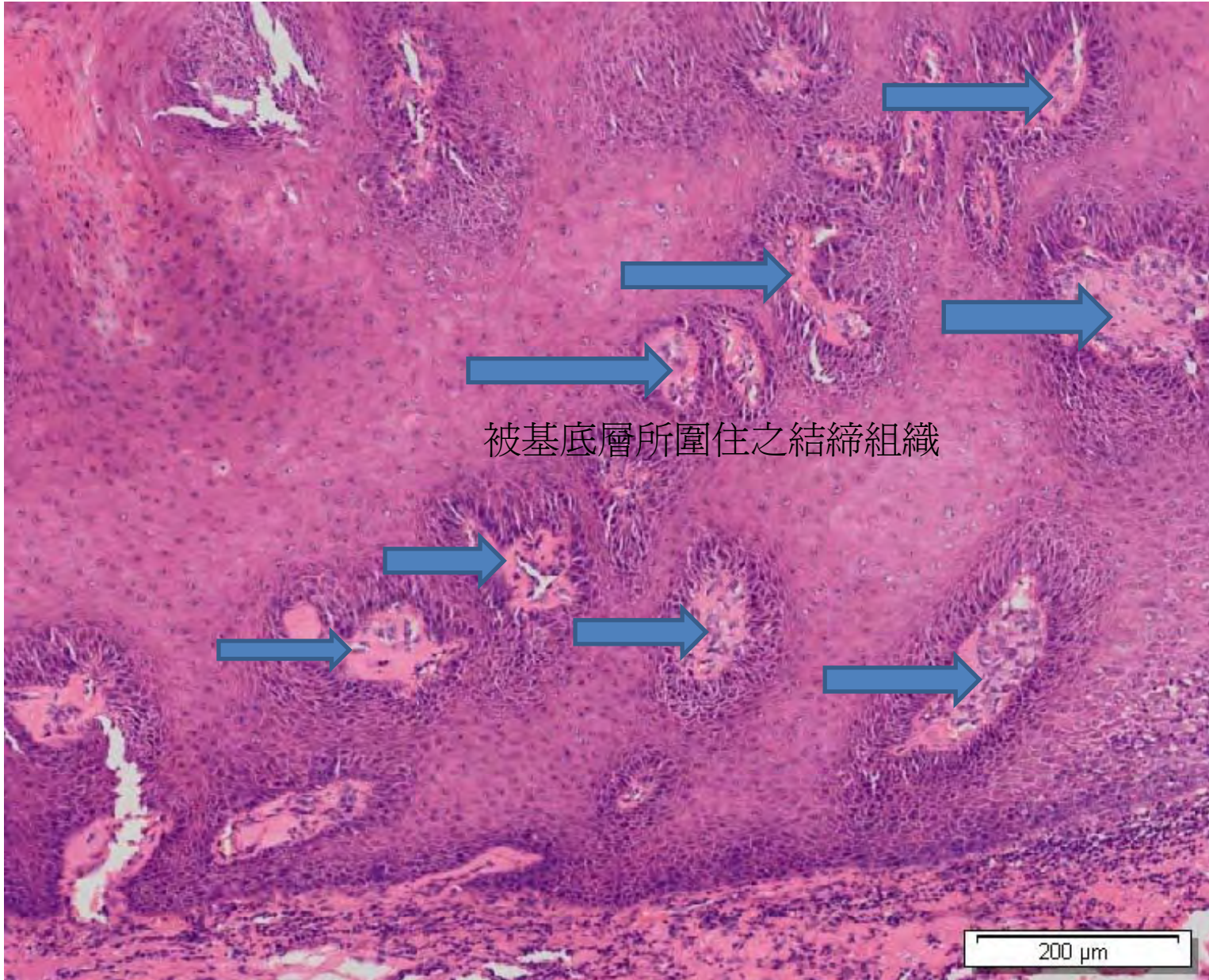
[Back](#)



<注意>請勿複製新投影片



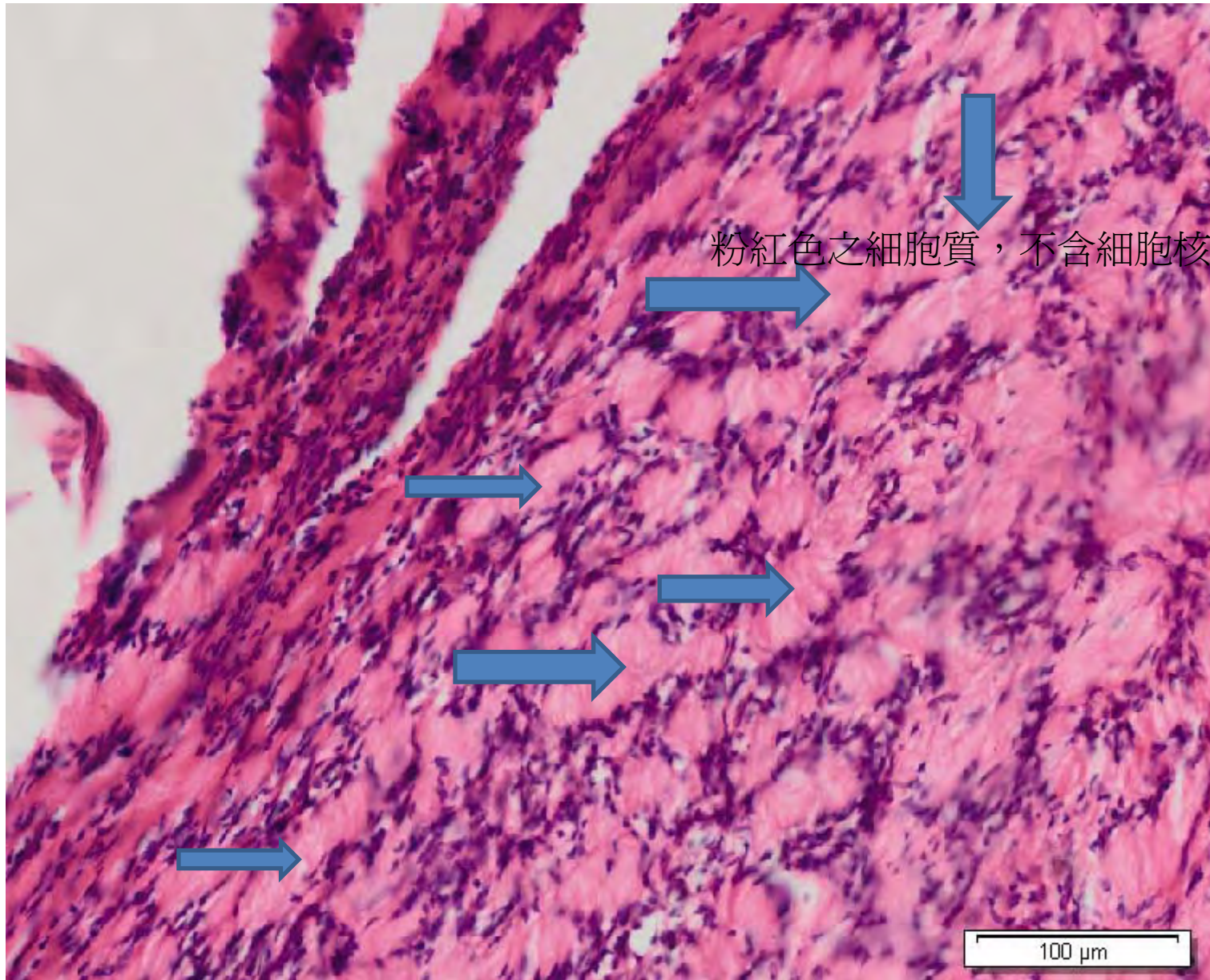
1. 請從題目1-8中找出並標示 Connective tissue core 之病理特徵



<注意>請勿複製新投影片



J. 請從題目1-8中找出並標示 **Verocay body** 之病理特徵



<注意>請勿複製新投影片